

Symptomatic Intraparenchymal Epididymal Cysts: Description of 11 cases

EVANGELIA SCHOINA, IOANNA GKALONAKI, IOANNIS TREVLIAS, CHRISTINA PANTELI, IOANNIS PATOULIAS

First Department of Pediatric Surgery, Aristotle University of Thessaloniki,
General Hospital “G. Gennimatas”, Thessaloniki, Greece

Corresponding author: Evangelia Schoina, M.D.
Alexandrou Ipsilantou 56, 54249, Thessaloniki, Greece
Phone: +30 695 197 12 47; E-mail: lia1997@hotmail.gr

Abstract: Epididymal cysts are benign cystic formations of the epididymis that usually appear in adolescence or early adulthood. Their frequency doubles after the age of 14–15. Obstruction in the epididymal efferent ductules with subsequent prostenotic dilatation of them, as well as dysgenesis due to hormonal disorders during fetal or postnatal life, are possible. At the 1st Department of Pediatric Surgery of A.U.Th. we treated 11 cases of boys at the age of 11–16 who presented with acute scrotum because of an epididymal cyst. The diagnosis was confirmed by ultrasound scanning. Due to persistent symptomatology, patients underwent surgical exploration and removal of the cyst. The postoperative care of the patients was uncomplicated with immediate remission of symptoms. In one case, ipsilateral acute epididymitis occurred after 10 days, which was successfully treated with antibiotic therapy. It is reported that approximately 50% of epididymal cysts involute within an average of 17 months. In conclusion, using the data obtained from the review, of the small in number of international bibliography studies, it is proposed conservative treatment of asymptomatic cysts with diameter smaller than 1 cm and surgical excision [1] of large asymptomatic cysts with diameter greater than 1 cm, which do not regress after a follow-up of 24–48 months, cysts, regardless of their diameter, responsible for persistent symptoms and in the manifestation of acute scrotal symptoms due to inflammation, intravesical bleeding or secondarily torsion of the epididymis.

Keywords: cyst, epididymis, painful scrotum, male adolescence.

Submitted: 12-Dec-2022; **Accepted in the final form:** 30-Aug-2023; **Published:** 30-Dec-2023.

Introduction

Intraparenchymal Epididymal Cysts (IECs) are benign, single or multiple compartment, with a clear fluid content and covered by cuboidal or cylindrical epithelium [1, 2]. The reported incidence of IECs according to Messina *et al.* study is 5–20% [1].



They are more common after the age of 40 [1, 2]. In a representative work by Niedzielski *et al.* who studied 45 cases of adolescents with IEC, it was found that in 75–80% of the cases there was solitary cyst, in 20% there were two — cysts — and in 5% there were 3 or more (unilateral or bilateral) [2].

The cause of the diagnostic investigation may be a) a painful scrotum b) the view of the intrascrotal spherical swelling followed by its palpation and diaphanoscopy by the clinician and c) the accidental finding of it in a scrotal ultrasound performed for other condition.

It should be noted that in 0.8% of adolescents who undergo a scrotal ultrasound, an IEC is accidentally found [1]. It is essentially an extra-testicular cystic lesion that has similarities with spermatocele regarding the composition of the fluid and the histology of the capsule. It differs from which a) in the location as the spermatocele emerges — almost always — from the head of the epididymis, while the IEC originates from any part of the epididymis and b) in the composition of the fluid as sperm is found in the spermatocele.

The purpose of this work is the submission of our proposal regarding the indicated therapeutic approach.

Material and Methods

In the last two years we treated 11 cases of boys at the age of 11–16 years (average: 10.4 years) with IEC. All patients had free personal medical history and experienced painful left (6/11 cases) or right (5/11 cases) hemiscrotum (Table1).

Table 1. Analysis of 11 cases of our study.

N.	Location	Episcopis Positive	Palpation Positive	Diagnostic evidence	Maximum diameter (cm)	Treatment
1	Head (R)	—	Yes	Ultrasound	1.8	Surgical
2	Head (L)	Yes	Yes	Ultrasound	2.2	Surgical
3	Body and Head (R)	—	Yes	Ultrasound	2.3	Surgical
4	Body (R)	—	—	Ultrasound	4	Surgical
5	Head (L)	—	Yes	Ultrasound	3.8	Surgical
6	Head (L)	Yes	Yes	Ultrasound	3.3	Surgical
7	Head (L)	—	—	Ultrasound	3.5	Surgical
8	Head (R)	—	—	Ultrasound	2.9	Surgical
9	Head (L)	—	—	Ultrasound	2.6	Surgical
10	Body and Tail (R)	—	—	Ultrasound	2.3	Surgical
11	Head (L)	—	Yes	Ultrasound	1.7	Surgical

During the clinical examination, the swelling corresponding to the IEC was evident in 2 cases (2nd and 6th case), while it was possible to palpate the mobile cystic formation with soft texture with clear sensitivity of the epididymal head (in 5/11 cases) (Fig. 1). The diaphanoscopy of the cystic lesion was indicative of the presence of fluid with thin consistency, inside it. The testicle was normotopic and painless. No sign of inflammation was observed with swelling and redness on the skin of the semiscrotum.

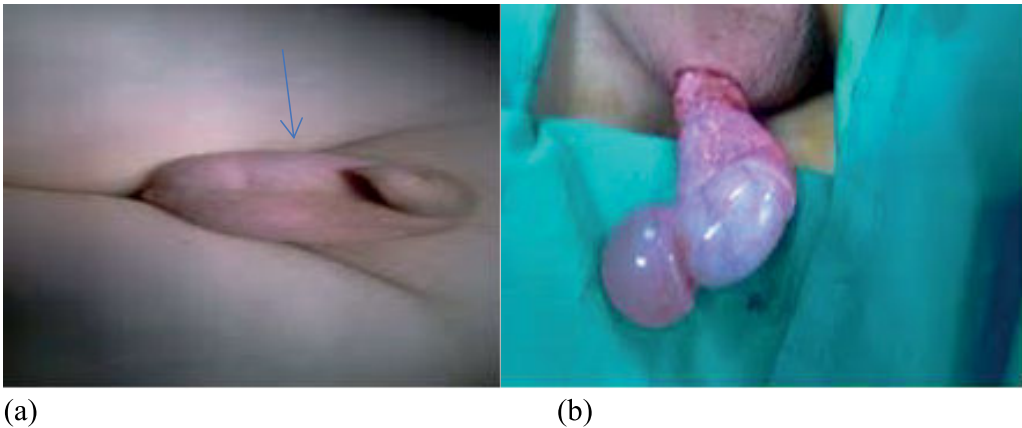


Fig. 1 (a, b). In the 1st case, the IEC was visible. The image of this cyst with diameter of 1.5 cm intraoperatively (b).

This was followed by an ultrasound examination a) of the scrotum which revealed a single-compartment thin-walled cyst without humps, within the parenchyma of the head of the epididymis, with diameter of 1.5–4 cm respectively and b) an ultrasound of the kidneys-ureters-bladder, with normal findings (Table 1, Fig. 2).

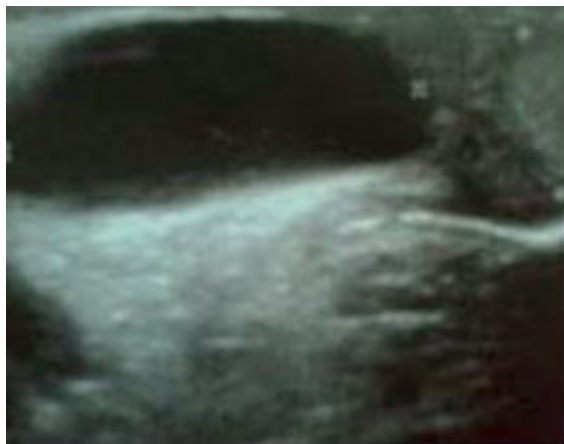

Fig. 2. Ultrasound imaging of the 2 cm diameter intraparenchymal epididymal cyst (3rd case).

Surgical treatment followed on an elective basis with general endotracheal anesthesia. The approach was standard with a transverse incision in the middle of the hemiscrotum, opening of the dart, the external spermatic, the cremaster and the internal spermatic fascia, the tunica vaginalis and albuginea and then exteriorization of the testis and epididymis. The intraparenchymal cyst in the head of the epididymis was identified in all cases and enucleated and removed without rupture (Fig. 3, 4).

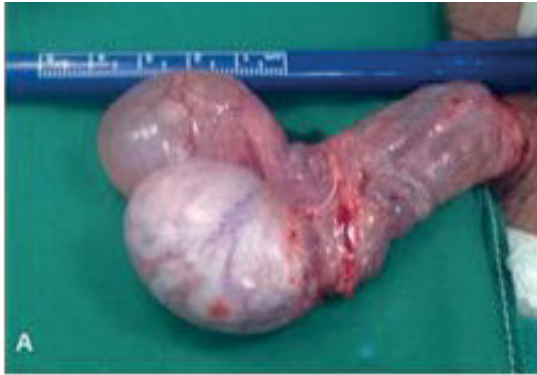

Fig. 3. IEC with diameter of 3.8 cm in the 4th case (testis and epididymis after their externalization from the hemiscrotum). Notice that the IEC occupies the head of the epididymis.

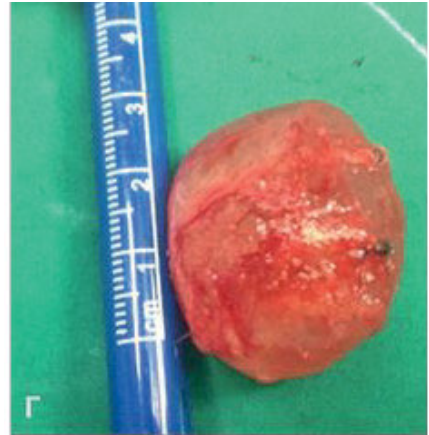


Fig. 4. The removed IEC of the 4th case with diameter of 3.8 cm.

The epididymal capsule was closed by continuous suturing with thin rapid absorbable sutures. The testis-epididymis complex was repositioned in the ipsilateral hemiscrotum, followed by closure of the surgical wound in anatomical order.

Results

An immediate remission of symptoms was observed postoperatively. There were no complications 2–6 months postoperatively. In the third case (14-year-old male with a cyst of 2 cm in diameter), discomfort occurred on the 10th postoperative day. Ultrasound examination showed epididymal swelling and hyperemia (findings consistent with epididymitis). The episode was successfully treated with oral antibiotic therapy for 10 days. There has been no recurrence of symptoms to date (6 months postoperatively).

The histological examination of the removed cysts showed an IEC with a smooth transparent wall and serous content without evidence of malignancy. None of these cysts contained spermatozoa, ruling out the entity of spermatocele.

Discussion

IECs are benign cystic formations of the epididymis [3]. This is a rare clinical entity especially in children with few references in the international bibliography. In a representative retrospective study of 11 years Homavoon *et al.* report on 20 boys with a mean age of 10.5 years with an IEC [4]. The frequency of IEC doubles after the age of 14 [2, 4]. At the 1st Department of Pediatric Surgery of Aristotle University Thessaloniki we dealt with 11 cases over 10 years.

The differential diagnosis of IECs must be made by the intrascrotal cystic lesions which can be categorised into intratesticular ones, from which the imaging distinction is easier, (simple testicular cyst, cyst of the fibrous membrane of the testis, epidermoid cyst) and extratesticular cysts (cystic lymphangioma of the epididymis, spermatocele, adenomatoid tumor of the epididymis) [5].

The etiopathogenesis of IECs is not known. They are often found in cryptorchidism, cystic fibrosis, von Hippel-Lindau disease, polycystic kidney disease as well as in prenatal exposure to diethylstilbestrol [3, 6]. Sinha *et al.* in their study describe a very rare case of IEC in a 32-year old man because of schistosomiasis [7]. Schistosomal epididymitis is a very rare condition. Worldwide, very few cases have been reported, especially in India.

Regarding the etiology of the disease, have been accused a) hormonal disorders from toxic factors that act either prenatally (diethylstilbestrol) or postnatally, b) the degenerative process and c) the pre-existing obstruction or narrowing of the epididymal tubules with consequent prostenotic dilatation that develops progressively a cystic structure (intraparenchymal cyst) and causing — possibly — pressure phenomena on the adjacent tubules [5]. In recent studies, the possible causal association of IEC with testicular dysgenesis syndrome is supported [8, 9].

Weatherly *et al.* underwent scrotal ultrasound in 91 men of reproductive age (67 fertile and 24 infertile). IECs were found in 46/67 (73%) fertile and 16/24 (67%) infertile men. Though the reason for the high prevalence of EC is unknown, there is no evidence to suggest that the presence of these cysts is associated with infertility [10].

Based on representative retrospective studies, the size of IEC has been found to vary between 3 mm and 3 cm [2–5]. One of the cysts we treated (case 4/11) was 4 cm in diameter, a finding suggesting that the dimensions may be greater than those reported in the international bibliography.

51.8–75% of IECs are asymptomatic and found accidentally while 25–49.2% cause symptoms and 50% of them regress spontaneously within a period of 12–17 months [3, 4]. Messina *et al.* observe that up to 60% of IEC regress spontaneously if below 3 cm in diameter [1]. According to Mukendi spontaneous resolution may occur with no need for surgical excision of cysts and can take up to 50 months: the average time to

complete involution varies from 4 to 50 months [11]. In our cases, the indication for surgical treatment was the persistent symptomatology of painful hemiscrotum.

Yin *et al.*, Niedzielski *et al.* and Hegazy *et al.* do not approve and recommend sclerotherapy in the developing testes of pubertal boys [2, 12, 13].

In conclusion, using the data obtained from the review, of the small in number of international bibliography studies, it is proposed:

- conservative treatment of asymptomatic cysts with diameter smaller than 1 cm and
 - surgical excision
1. of large asymptomatic cysts with diameter greater than 1 cm, which do not regress after a follow-up of 24–48 months
 2. cysts, regardless of their diameter, responsible for persistent symptoms
 3. in the manifestation of acute scrotal symptoms due to inflammation, intravesical bleeding or secondarily torsion of the epididymis.

Conflict of interest

None declared.

References

1. Messina M., Fusi G., Ferrara F., Bindi E., Pellegrino C., Molinaro F., Angotti R.: A rare cause of acute scrotum in a child: torsion of an epididymal cyst. Case report and review of the literature. *Pediatr Med Chir.* 2019 Jun 21; 41 (1). doi: 10.4081/pmc.2019.210.
2. Niedzielski J., Miodek M., Krakos M.: Epididymal cysts in childhood — conservative or surgical approach? *Pol Przegl Chir.* 2012; 84: 406–410.
3. Posey Z.Q., Ahn H.J., Junewick J., Chen J.J., Steinhardt G.F.: Rate and associations of epididymal cysts on pediatric scrotal ultrasound. *J Urol.* 2010; 184: 1739–1742.
4. Homavoon K., Suhre C.D., Steinhardt G.F.: Epididymal cysts in children: natural history. *J Urol.* 2004; 171: 1274–1276.
5. Woodward P.J., Schwab C.M., Sesterhenn I.A.: From the archives of the AFIP: extra testicular scrotal masses: radiologic-pathologic correlation. *Radiographics.* 2003; 23: 215–240.
6. Steinhardt G.F.: Editorial comment to epididymal cyst: Not always a benign condition. *Int J Urol.* 2012; 20: 458.
7. Sinha V., Shankar M., Sardana N., Aggarwal R.: A Rare Case of Epididymal Cyst Due to Schistosomiasis. *Cureus.* 2019 Sep 25; 11 (9): e5755. doi: 10.7759/cureus.5755.
8. Sharpe R.M.: Hormones and testis development and possible adverse effects of environmental chemicals. *Toxicol Lett.* 2001; 120: 221.
9. Skakkebaek N.E., Rajpert-Demeyts E.: Testicular dysgenesis syndrome: an increasingly common developmental disorder with environmental aspects. *Hum Reprod.* 2001; 16: 972.
10. Weatherly D., Wise P.G., Mendoca S., Loeb A., Cheng Y., Chen J.J., Steinhardt G.: Epididymal Cysts: Are They Associated With Infertility? *Am J of Mens Health.* 2018; 12 (3): 612–616. doi: 10.1177/1557988316644976.

11. *Mukendi A.M.*: Bilateral epididymal cysts with spontaneous resolution. *Clin Case Rep.* 2020; 8: 2689–2691. <https://doi.org/10.1002/ccr3.3199>.
12. *Yin Z., Meng X.*: Chapter 4 — General techniques of scrotoscopic surgery. In: Yang J. ed. *Scrotoscopic Surgery*. Cambridge, MA: Academic Press. 2019; 23–53.
13. *Hegazy A.F., Atrebi M.*: Management challenges of epididymal cysts in childhood. *Med J Cairo Univ.* 2012; 80: 909–912.