

Pigmented villonodular synovitis

ARTUR FAŁEK¹, JOANNA NIEMUNIS-SAWICKA^{2,3}, KATARZYNA WRONA¹,
GRZEGORZ SZCZYPIÓR³, LUDOMIRA RZEPECKA-WEJS⁴, KATARZYNA CIĘSZCZYK⁵,
MACIEJ BURDAN¹, MICHAŁ PUDERECKI⁵, PAULINA BURZEC¹,
BARBARA MARZEC-KOTARSKA⁵, JUSTYNA SZUMIŁO⁵, FRANCISZEK BURDAN^{1,6}

¹Human Anatomy Department, Medical University of Lublin; Lublin, Poland

²2nd Radiology Department, Medical University of Gdańsk; Gdańsk, Poland

³MRI Unit of Maritime Medical Center; Gdańsk, Poland

⁴Goris-Med; Gdańsk, Poland

⁵Clinical Pathomorphology Department, Medical University of Lublin; Lublin, Poland

⁶Radiology Department, St Johns' Cancer Center; Lublin, Poland

Corresponding author: prof. dr hab. Franciszek Burdan, MD, PhD, ERT
Experimental Teratology Unit, Human Anatomy Department, Medical University of Lublin
ul. Jaczewskiego 4, 20-074 Lublin, Poland
Phone: +48 814 486 029; Fax: +48 814 486 021; E-mail: fb3@wp.pl

Abstract: Pigmented villonodular synovitis (PVNS) is a benign disease that rarely undergoes malignant transformation. There are two types of disease: localized (nodular tenosynovitis) and diffused (pigmented villonodular synovitis/tenosynovitis) with intra- or extra-articular locations. The second one is limited to synovium of the burse (PVNB) or tendon sheath (PVNTS). The intraarticular lesions are usually located in the knee, hip, ankle and elbow joints. Histologically, PVNS is a tenosynovial giant cell tumor, characterized by proliferation of two types of mononuclear cells — predominantly small, histiocyte-like cells and larger cells with dense cytoplasm, reniform or lobulated nucleus, with accompanying multinucleated giant cells and macrophages overloaded with hemosiderin that give typical image on MRI — currently selected as a gold standard for its diagnosis. The classic X-ray and CT are non-specific but similar to ultrasound should be used to evaluate disease progression and treatment response if radiotherapeutic and pharmacological methods were selected for treatment. An open arthroscopic surgery could also be applied in selected cases.

Key words: pigmented villonodular synovitis, PVNS, tenosynovial giant cell tumor, epidemiology, diagnosis.

Pigmented villonodular synovitis (PVNS) is a rare disease associated with a benign proliferation of the synovial membrane, described for the first time in 1852 by Édouard-Pierre-Marie Chassaignac (1804–1979) as a nodular damage of synovial membrane. In 1941 Henry L. Jaffe (1896–1979) introduced a current classification of the disease that contains intra- and extra-articular changes, including pigmented villonodular synovitis (PVNS), bursitis (PVNB) and tenosynovitis (PVNTS), limited to synovium of the joint capsules, bursas and or tendon sheaths, respectively [1]. Proliferation progresses gradually. It is usually monoarticular and 80% of the cases are limited to the knee joint [2]. The process is benign however, a few cases of malignant transformation were reported in literature [1, 3].

The etiology of the disease is unclear [4]. Generally, it is characterized by a localized or diffuse growth of synovial villi with hemosiderin accumulation [3]. It occurs as a localized or, more frequently, a diffuse form (80%) [5]. In both types, histological features are similar, however, biological behavior, choice of treatment and prognosis are different [4]. Diffuse form refers to large joints such as knee, hip, ankle and elbow, respectively. It is rarely found in the small joints of the spine, hands or feet, as well as the temporomandibular ones [1].

Epidemiology

PVNS is uncommon and in global scale it applies to 1,8 million people worldwide [4, 6, 7]. Statistically, two new cases per million population are diagnosed each year. Generally, it usually occurs in middle-aged people (between 2nd and 5th decade of life) [2]. However, cases limited to the hip (15% of the total case number) were observed between 2nd and 3rd decade [8]. The youngest reported patient was a one-year-old child [6].

Etiology

The etiology of PVNS is unknown. It is thought to be associated with previous trauma, intra-articular bleeding or chronic inflammation [2]. Chromosomal anomalies such as trisomy 5 and 7 or monoclonality features were found [1, 2]. Lipid metabolic disorder linked with local joint lipid abnormalities was also postulated [8].

Clinical manifestation

Clinical features of PVNS are ambiguous (Table 1). The main symptom is the escalated pain of the joint with the disease advancement. It may be located in the knee or hip areas, however, some patients complained about the pain in the groin. Chronic edema which leads to limited joint movement and consequently its stiffness, is frequently

noted. The soft tissue mass is rarely found but the disease may potentially affect local muscles, bones, tendons and skin. The disease usually affects a single joint, however, occurrence in many joints was also reported. It is mostly diagnosed in children who reveal other abnormalities such as: vascular lesions, cherubism, multiple lentiginos syndrome, extremity lymphedema, Noonan syndrome and jaw lesions [2, 8]. The average period between occurrence of the disease and the appropriate diagnosis was 4 years. Ambiguous radiological image, symptoms variability, and low intensity pain at an initial stage of the disease result in a delayed diagnosis [2, 8, 9].

Table 1. Incidence of clinical manifestations in intra- and extra-articular forms of PVNS [1].

Intra-articular PVNS	Extra-articular forms (PVNB, PVNTS)
Pain (79–90%)	Mass of soft tissues (83–99%)
Oedema (72–79%)	Pain (22–71%)
Joint dysfunction (26–28%), mass of soft tissues (6–19%)	Joint dysfunction and edema (0–4%)

Macroscopic and microscopic morphology

According to the current World Health Organization (WHO) classification, there are two main types of the disease: tenosynovial giant cell tumor, localized type (synonym: nodular tenosynovitis) and tenosynovial giant cell tumor, diffuse type (synonym: pigmented villonodular synovitis/tenosynovitis). The first one is presented as a tumor of usually 5–40 mm, well-circumscribed, encapsulated, lobulated, grey with yellow-brown areas, while the second one is bigger (>50 mm), firm or spongy and multicolored [10].

On histological examination, localized PVNS is a well-separated tumor surrounded by a fibrous capsule [8]. Contrary to the above description, diffuse type of PVNSs are not encapsulated and demonstrated infiltrative growth [1, 10]. The lesions are composed of mixture of cells with different proportions (Fig. 1). There are two types of mononuclear cells: small in size, histiocyte-like cells, which constitute the main cell tumor composition and larger cells with pale or amphophilic cytoplasm and kidney-shaped or lobulated nuclei with nucleoli. They are accompanied by multinucleated osteoclast-like giant cells, foamy macrophages and hemosiderin-laden macrophages [3].

Among 20% of diffuse type of PVNS, giant cells are not observed which makes it hard for the disease to be diagnosed. Mitotic activity is usually low — <10 mitoses per 10 HPF (high-power fields) [1, 8]. Necrosis is rare and in localized forms hyalinization can be seen.

In immunohistochemical examinations larger mononuclear cells express calretinin and can be positive for typical muscle marker — desmin. Smaller histiocyte-like cells express CD68, CD163, and CD45, whereas multinuclear giant cells reveal osteoclast-type expression profile, i.e. CD68, CD45 and tartrate-resistant acid phosphatase (TRAP) [10].

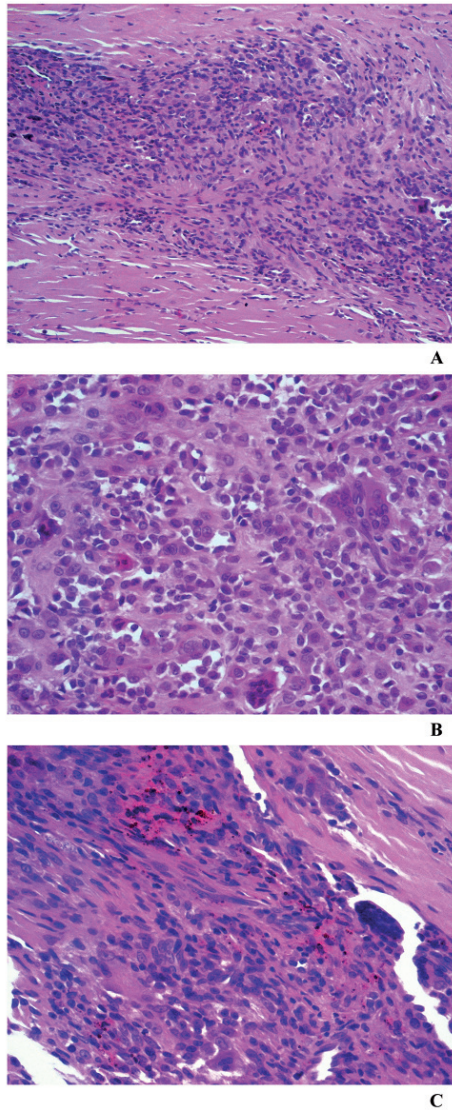


Fig. 1. Pigmented villonodular synovitis, localized type. The lesion is composed of mixture of mononuclear cells and scattered multinucleated osteoclast-like giant cells and hem siderin-laden macrophages (HE, objective magn. A — 10 \times ; B–C — 20 \times).

It has to be stressed that diffuse intra-articular form of PVNS may resemble various malignancies such as rhabdomyosarcoma, synovial sarcoma, or epithelioid sarcoma. Therefore, in order to make a correct diagnosis, the results of histological evaluation of the lesion has to be correlated with clinical symptoms and radiological findings [8].

Imaging morphology

Radiological examination plays an important role in a correct diagnosis, treatment planning and monitoring of the PVNS. Major examination techniques include: X-ray imaging, CT (computed tomography) and MRI (magnetic resonance imaging) [8]. A scintigraphy SPECT examination with the use of Tl-201 is rarely applied due to its low specificity, lack of correlation with necrosis, lower dimensional resolution and possibility to miss small changes [11].

Basic examination includes X-rays, however, it may be endangered with the lack of deviation at an early stage of the disease. In further stages bone erosions, subchondral cysts and bone loss can be observed [3, 8]. Diffuse intra-articular feature of PVNS is commonly characterized by effusion and external bone erosion on both sides of the joint, while the joint space initially remains undisturbed [1].

Bone erosions can be mainly found in the tight joints as it happens in hip, shoulder, foot bone or elbow, whereas a knee joint is less susceptible to bone erosions due to large capacity of the joint. Juxta-articular osteoporosis does not commonly occur in an X-ray picture of PVNS [3, 12]. It is rather rare to find cases leading to a complete bone and joint damage within the period of a few months [8]. Calcification is not usually observed [1]. However, all changes are of little specificity and thus more precise examination needs to be applied [13]. Osteolytic changes in hip joints need to be differentiated from osteoarthritis, where contrary to its bone changes referred to PVNS, do not only result from external force but they are also linked with pressure increase inside the joint caused by their mass extension [1, 3, 8].

There are two radiological classifications to assess PVNS stage: by Lequesne and Gotelis (Table 2) [8].

Table 2. Radiological classification of PVNS stage based on classic X-rays findings, according to Lequesne and Gotelis [8].

Stage	Lequesne	Gotelis
1	“evocative” — vast subchondral cysts of a hip with or without narrowing of the joint gap (62% among the examined cases)	photography without any deviations (2% of cases)
2	“pseudo-coxitis” — local narrowing of the joint gap in the area of the load, with deep bone erosion of the head and/or the acetabulum with possible occurrence of subchondral cysts outside the affected area??? (in 16% of patients examined)	lytic changes, however, without the narrowing of the joint cavity (found in 47% of cases)
3	“pseudo-coxarthrosis” — advanced narrowing of the joint gap due to the expansion of subchondral cysts in 14% of patients examined)	large lytic lesion which leads to the narrowing of the joint area (found among 51% of cases)

In arthrography, a diffuse intra-articular form may reveal vast synovial thickening with villus or nodular structures that extend into the joint. When referred to a local intra-articular case, there appears a single tumor area of synovium. Sample of the fluid taken before contrast appliance may be of blood-red color (69–75% of cases), yellow (22–25%) or brown (9%) [1].

In most cases, the indicative modality applied in diagnosis is an ultrasound (Fig. 2). It is not a peculiar examination but at least it allows to determine the nature

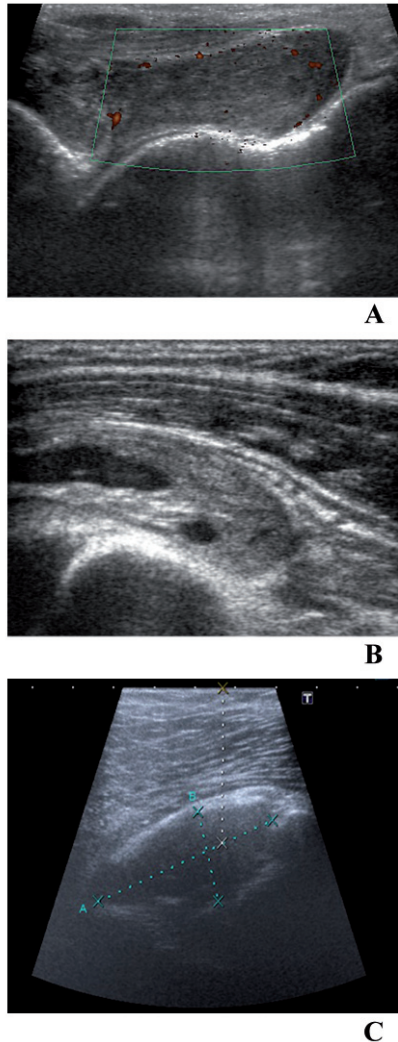


Fig. 2. Pigmented villonodular synovitis, localized type in the tendon sheath of the index. Lineal (A, B) and ultrasound convex transducer, with (A) and without Doppler (B, C).

of the mass — in terms of fluid or a solid [2]. Such method of examination may help to confirm the effusion in the joint and hypoechogenic thickening of synovial membrane, external erosion of the bone underneath, whereas in Doppler examination a high degree of vessel structure can be observed [3]. However, significant neo-vascularisation, mild arteriovenous shunting and tumor blush, which may resemble malignant neoplasm, were previously confirmed in angiography. In advanced cases CT is applied. Usually, it can show only joint effusion and hypertrophic synovial membrane occurs as tissue mass which, due to hemosiderin occurrence, can be more hyperdense compared with neighboring muscles [1]. CT examination is much less efficient to carry out a detailed study of synovial membrane and soft tissues, even though its significant advantage is the opportunity to perform CT-guided biopsy of synovium and following to establish a proper diagnosis. The examination allows a precise analysis of subchondral cysts occurrence and to diagnose minor bone erosions which cannot be visible in X-ray picture [8]. In case of PVNS referred to temporomandibular joint, CT examination can be helpful in assessment of mandibular condyle and a temporal bone. Moreover, the examination may help with differential diagnosis with other changes which may be located in the same area, such as chondrosarcoma or synovial chondromatosis [14]. In comparison to MRI examination, the range of changes is not so well-visible due to rather restricted contrast division [1].

Currently, MRI is the golden standard in PVNS diagnosing [8]. By its precise localization, range of the changes and assessment of other structures, such as tendon sheath and ligaments, it allows the accurate assessment before the surgery and prevents from impartial tumor resection which leads to the disease recurrence [2, 4]. Moreover, it most accurately assesses effectiveness of the treatment, allows the continuous control in case of the disease recurrence and reveals any post-surgery aseptic necrosis [8]. The examination can detect synovial membrane and soft tissue growth with hemosiderin sedimentation and bone erosion [15]. MRI examination should include T1-weighted sequences with or without contrast enhancement as well as T2-weighted sequences with and without fat saturation [8]. A characteristic feature in recognition of typical changes for PVNS confirms a low signal in both sequences but especially in T2, which results from paramagnetic activity of hemosiderin (Table 3) [4, 8, 9, 11, 14, 16–19]. An intermediate signal may be detected if the amount of hemosiderin found in tissue mass is rather low [17]. There can be observed a reactive joint effusion which may manifest as an intermediate signal on T1- and a high signal on T2-weighted images (Fig. 3). Once an increase is detected, it is mostly linked with an inflammation and increased number of blood vessels of synovium [14]. The signal characteristics does not differ depending on the location of the examined change [11].

Table 3. MRI finding in PVS patients [3, 14].

T1	low to intermediate signal
T1 C+ (Gd)	changeable enhancement
T2	low to intermediate signal, infrequently the area of high signal — probably due to joint fluid occurrence or inflammation
STIR	high signal
GE	low signal and may demonstrate blooming — very useful option in diagnosing and differentiating PVNS

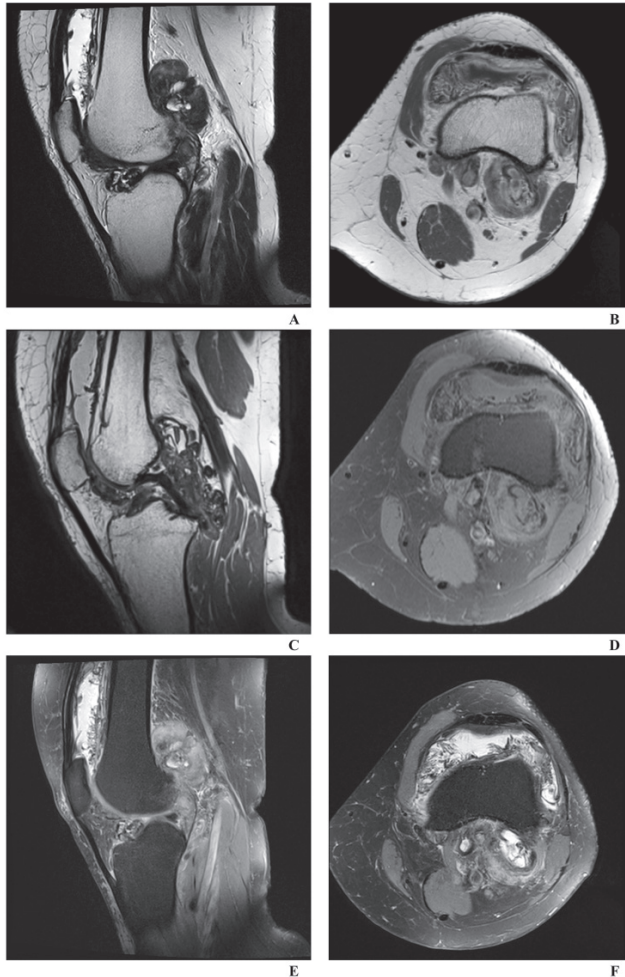


Fig. 3. Pigmented villonodular synovitis, localized type of the knee joint. Sagittal (A, C, E) and axial images (B, D, F) in T2- (A), T1-weighted (B, C) and T1-weighted with fat saturation (D) and T2-weighted with fat saturation (E, F).

Various pathological conditions should be included in differential diagnosis [17, 20–27]:

- synovial chondromatosis — radiographs: intra-articular calcifications (70–95% of cases) of similar size and shape, typical “ring-and-arc” chondroid mineralization, extrinsic erosion of bone (20–50% of cases). MRI — T1: low to intermediate signal, T2: high signal, echo gradient: may reveal blooming artifact
- rhabdomyosarcoma — X-ray examination: calcification in tumor mass, metastases, bone defects. In MRI — T1 — low to intermediate signal, T2 — high signal, T1 c (Gd) — shows significant reinforcement
- fibroma of tendon sheath — MRI: T1 — evenly low, T2 — evenly low, STIR low, an increase after applying contrast
- synovial sarcoma — MRI: T1 — iso- or slightly hyperintensive, T2 — hyperintensive, various appearance of synovial cell sarcomas on fluid-sensitive sequences is called “triple sign” and due to the tendency of synovial sarcoma to bleed, there might be also areas of fluid-fluid levels called “bowl of grapes”. T1 C (Gd) — following reinforcement can be found — disseminated (40%), marginal type (20%) or heterogenic (40%). Genetics — cytogenetic aberrations of translocation t(X;18) (found even among 90% of cases)
- amyloid arthropathy — diversity mainly based on other organ symptoms, histopathological examination, in X-ray examination changes which are similar to PVNS may occur, in MRI examination: T1 — low to intermediate, T2 — low to intermediate
- haemophilic arthropathy — more frequently juxta-articular osteoporosis occurs, interview, clinical feature (idiopathic bleeding from various places), laboratory examination, in X-ray picture symmetric loss of joint cartilage, apophyses; MRI image is similar to PVNS
- lipoma arborescens — histopathologic examination (lack of large cells containing hemosiderin residue), MRI examination: synovium masses, signal intensity and structure similar to fat in all sequences, dampening signal in STIR, lack of magnetic effect connected with hemosiderin
- rheumatoid arthritis — typical long clinical history and manifestation, laboratory tests, image examinations: joint area osteoporosis, geodes, narrowing of the joint cavity, muscular atrophy, fibroid or osseous adhesions.

Treatment

There are a few therapeutic options for patients with PVNS: surgery, radiotherapy, pharmacology or a combined solution of the enumerated methods [1]. Basic therapy is focused on elimination of lesions caused by the disease either by arthroscopic method, or by an open surgery [2]. It allows pain relief and return of joint functions.

A complete synovectomy is a desirable standard, which denotes a complete removal of all pathological lesions. In some cases, especially in diffuse form of PVNS, it may be difficult due to the risk of vessel and nerves damaging [28]. Open arthrotomy with synovectomy increases probability of a complete resection of the lesion, but it still requires immobilizing and longer recovery. A complete treatment is more probable in the case of the localized forms (also when referred to PVNB or PVNTS). Thus, a surgical procedure is the only fully sufficient method of treatment. Diffuse form of the disease is much more complicated and may require an additional therapy simultaneous with the surgical resection [1]. In lesions located in hip joint, application of arthroscopy is limited, since local forms of PVNS are rare in that location [4]. Surgical treatment is the best solution, since it allows elimination of all pathological lesions, including juxta-articular subchondral cysts. Replacement of subchondral capsules by their homological or autologous cancellous decreases the risk of PVNS recurrence. Generally, it is not advised to use arthroscopy in diffuse form of PVNS due to a difficulty in assessment of the entire synovial membrane — and thus a complete synovectomy cannot be obtained [5, 8].

A local recurrence after treatment was reported in 18–46% of patients [2]. However, in 8–56% of those cases an external beam radiation, radioactive synovectomy or a surgery has been successfully applied [3, 4, 7]. In unique cases, it is necessary to perform a complete alloplastic surgery of the entire knee joint [17]. A recurrence may be linked with incomplete resection of satellite nodules in the area of initial change and therefore MRI screening plays a significant role in their detection. Among the factors which increase the risk of recurrence are the following: location of the disease (more common in the knee due to the large capacity of the joint and difficulty in performing complete synovectomy), history of previous surgeries and positive surgical margins [1].

Radiotherapy may be used as a supplement of a surgical treatment, especially in diffuse forms, incomplete resection and recurrence [4, 9]. Radiation doses of 20–50 Gy are supplied in 15–25 fractions, starting with the period of 6–8 weeks following the surgery [1]. Treatment may also include intra-articular injection of radioactive isotope. There are a few isotopes in use, they all have similar features — they emit beta radiation. Such procedure is ambulatory, and the injection can be supported by a steroid to decrease inflammation, which may be caused by treatment itself. To confirm the needle position before isotope injection, arthrography is used. Clinical results are often satisfactory and intra-articular radiosynovectomy has an excellent safety profile, especially when administered in large joints [1, 7, 9, 28]. However, in a single case of the examination after applying yttrium (Y-90) in ankle joints, skin ulceration occurred, which required surgical intervention [29].

Nowadays, a treatment with anti-TNF (tumor necrosis factor) antibodies has been also suggested. After applying monoclonal antibody (infliximab), there was a gradual

improvement in clinical symptoms, decrease of pain and thus avoided or delayed bone and joint destruction. Among patients who were treated with this method, despite minor changes in MR examination after applying medicine, histopathological examination confirms a significant decrease in number of synovial membrane macrophages [1, 29].

Conflict of interest

None declared.

Abbreviations

CT	— computed tomography
Gd	— gadolinium
GE	— gradient echo
MRI	— magnetic resonance imaging
PVNB	— pigmented villonodular bursitis
PVNS	— pigmented villonodular synovitis
PVNTS	— pigmented villonodular tenosynovitis
STIR	— short tau inversion recovery
TNF	— tumor necrosis factor
TRAP	— tartrate-resistant acid phosphatase
WHO	— World Health Organization

References

1. *Murphey M.D., Rhee J.H., Lewis R.B., Fanburg-Smith J.C., Flemming D.J., Walker E.A.*: Pigmented villonodular synovitis: radiologic-pathologic correlation. *Radiographics*. 2008; 28: 1493–518.
2. *Daoud J., Aouad D., Hassan Y., El Rassi G.*: Localized pigmented villonodular synovitis of the posterior knee compartment with popliteal vessel compression: a case report of arthroscopic resection using only anterior knee portals. *Case Rep Orthop*. 2018; 2018: 7532358.
3. *Tritschler P., Baudrez V., Mutijima E.*: Diffuse pigmented villonodular synovitis of the subtalar joint. *J Belg Soc Radiol*. 2018; 102: 11.
4. *Duan Y., Qian J., Chen K., Zhang Z.*: Necessity of adjuvant postoperative radiotherapy for diffuse pigmented villonodular synovitis of the knee: a case report and literature review. *Medicine (Baltimore)*. 2018; 97: e9637.
5. *Roman-Ramos M., Cariati P., Cabello-Serrano A., Garcia-Martin M., Garcia-Medina B.*: Arthroscopic approach for treating a pigmented villonodular synovitis of TMJ. A case report. *J Clin Exp Dent*. 2017; 9: e312–e314.
6. *Karami M., Soleimani M., Shiari R.*: Pigmented villonodular synovitis in pediatric population: review of literature and a case report. *Pediatr Rheumatol Online J*. 2018; 16: 6.
7. *Park G., Kim Y.S., Kim J.H., Lee S.W., Song S.Y., Choi E.K., Yi S.Y., Ahn S.D.*: Low-dose external beam radiotherapy as a postoperative treatment for patients with diffuse pigmented villonodular synovitis of the knee: 4 recurrences in 23 patients followed for mean 9 years. *Acta Orthop*. 2012; 83: 256–260.

8. Steinmetz S., Rougemont A.L., Peter R.: Pigmented villonodular synovitis of the hip. *EFORT Open Rev.* 2017; 1: 260–266.
9. Serra T.Q., Morais J., Gonçalves Z., Agostinho F., Melo G., Henriques M.: An unusual case of diffuse pigmented villonodular synovitis of the shoulder: a multidisciplinary approach with arthroscopic synovectomy and adjuvant radiotherapy. *Eur J Rheumatol.* 2017; 4: 142–144.
10. Fletcher C.D.M., Bridge J.A., Hogendoorn P., Mertens F. (eds.): *WHO Classification of tumours of soft tissue and bone.* WHO, Geneva 2013.
11. Lynskey S.J., Pianta M.J.: MRI and thallium features of pigmented villonodular synovitis and giant cell tumours of tendon sheaths: a retrospective single center study of imaging and literature review. *Br J Radiol.* 2015; 88: 20150528.
12. Nassar W.A., Bassiony A.A., Elghazaly H.A.: Treatment of diffuse pigmented villonodular synovitis of the knee with combined surgical and radiosynovectomy. *HSS J.* 2009; 5: 19–23.
13. Xie G.P., Jiang N., Liang C.X., Zeng J.C., Chen Z.Y., Xu Q., Qi R.Z., Chen Y.R., Yu B.: Pigmented villonodular synovitis: a retrospective multicenter study of 237 cases. *PLoS One.* 2015; 10: e0121451.
14. Allen A., Saran N.: Recurrent pigmented villonodular synovitis of the temporomandibular joint. *Radiol Case Rep.* 2018; 13: 499–502.
15. Lu H., Chen Q., Shen H.: Pigmented villonodular synovitis of the elbow with radial, median and ulnar nerve compression. *Int J Clin Exp Pathol.* 2015; 8: 14045–14049.
16. Murphey M.D., Rhee J.H., Lewis R.B., Fanburg-Smith J.C., Flemming D.J., Walker E.A.: Pigmented villonodular synovitis: radiologic-pathologic correlation. *Radiographics.* 2008; 28: 1493–1518.
17. Fernandes T.L., Videira L.D., Sasaki S.U., Natalino R.J.M., Almeida A.M., Pedrinelli A., Hernandez A.J.: Bilateral localized pigmented villonodular synovitis of the knee: Case report and review. *Acta Ortop Bras.* 2018; 26: 183–186.
18. Bhatnagar K., Bawa A.S., Narang V., Kaur P.: Pigmented villonodular synovitis of thumb — a cytological diagnosis. *J Clin Diagn Res.* 2017; 11: ED18–ED20.
19. Parmar H.A., Sitoh Y.Y., Tan K.K., Teo J., Ibet S.M., Hui F.: MR imaging features of pigmented villonodular synovitis of the cervical spine. *AJNR Am J Neuroradiol.* 2004; 25: 146–149.
20. De Filippo M., Rovani C., Sudberry J.J., Rossi F., Pogliacomì F., Zompatori M.: Magnetic resonance imaging comparison of intra-articular cavernous synovial hemangioma and cystic synovial hyperplasia of the knee. *Acta Radiol.* 2006; 47: 581–584.
21. Sheldon P.J., Forrester D.M., Leach T.J.: Imaging of intraarticular masses. *Radiographics.* 2005; 25: 105–119.
22. Murphey M.D., Vidal J.A., Fanburg-Smith J.C., Gajewski D.A.: Imaging of synovial chondromatosis with radiologic-pathologic correlation. *Radiographics.* 2007; 27: 1465–1488.
23. De Schepper A.M., Vanhoenacker F.M., Parizel P.M., Gielen J.L. (eds.): *Imaging of soft tissue tumors.* Springer Verlag, Berlin 2017.
24. Kransdorf M.J., Murphey M.D.: *Imaging of soft tissue tumors.* Lippincott Williams & Wilkins, Philadelphia 2006.
25. Hitora T., Yamamoto T., Akisue T., Marui T., Nagira K., Ohta R., Kurosaka M.: Fibroma of tendon sheath originating from the knee joint capsule. *Clin Imaging.* 2002; 26: 280–283.
26. Murphey M.D., Gibson M.S., Jennings B.T., Crespo-Rodríguez A.M., Fanburg-Smith J., Gajewski D.A.: From the archives of the AFIP: Imaging of synovial sarcoma with radiologic-pathologic correlation. *Radiographics.* 2006; 26: 1543–1565.
27. Llauger J., Palmer J., Rosón N., Bagué S., Camins A., Cremades R.: Nonseptic monoarthritis: imaging features with clinical and histopathologic correlation. *Radiographics.* 2000; 20: S263–78.
28. Kapoor C., Jhaveri M., Soni R., Shah M., Rathi P., Golwala P.: Pigmented villonodular synovitis of the knee joint: a case report. *Cureus.* 2016; 8: e816.
29. Kinra P., Varghese B.K.: Pigmented villonodular synovitis: dorsum foot. *Med J Armed Forces India.* 2007; 63: 294–296.