

Syndrome of canal of Guyon — definition, diagnosis, treatment and complication

PAWEŁ DEPUKAT¹, EWA MIZIA¹, MARCIN KUNIEWICZ¹, TOMASZ BONCZAR¹,
MAŁGORZATA MAZUR¹, PIOTR PEŁKA², IZABELA MRÓZ¹, MARCIN LIPSKI¹,
KRZYSZTOF TOMASZEWSKI¹

¹Department of Anatomy Jagiellonian University Medical College
ul. Kopernika 12, 31-034 Kraków, Poland

²Department of Orthodontics Jagiellonian University Medical College
ul. Montelupich 4, 31-155 Kraków, Poland

Corresponding author: Paweł Depukat, MD, PhD, Department of Anatomy, Jagiellonian University Medical College
ul. Kopernika 12, 31-034 Kraków, Poland; E-mail: depukatp@poczta.onet.pl

Abstract: Syndrome of canal of Guyon is the second after carpal tunnel syndrome, compression syndrome in the wrist. Opposite to median nerve compression, ulnar nerve compression is not very popular. However it impairs functioning of the hand even more than median nerve lesion. Authors deal with definition, possible diagnostic methods, treatment and most frequent complication.

Key words: ulnar nerve, wrist, Guyon's canal.

Definition

Syndrome of Guyon's canal is a complex of symptoms of progressive impairment of the ulnar nerve functioning, secondary to chronic, mechanical lesion of the nerve within canal of Guyon [1]. Depending on the location of the lesion within Guyon's canal, the symptoms may show different forms. They are similar to the symptoms of the groove for ulnar nerve, excluding the disturbances in the cutaneous innervation of the dorsum of the hand. This feature is associated with the origin of ramus dorsalis manus, about 5–8 cm proximal from the Guyon's canal. Traditionally the lesions seen in syndrome of Guyon's canal are divided following the subdivision proposed by Shea and McClain [2] (Fig. 1).

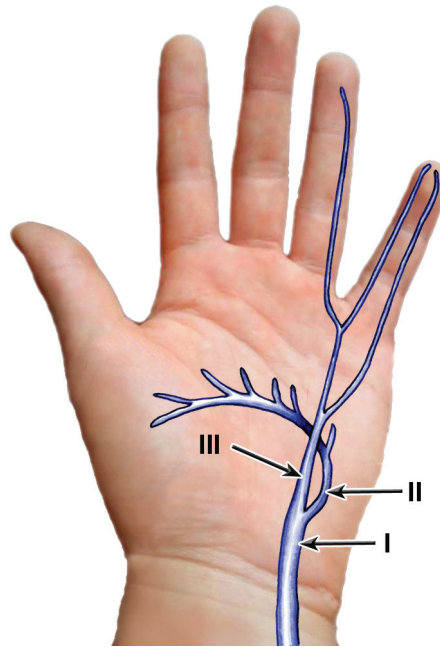


Fig. 1. Shea and McClain's subdivision of the lesions of ulnar nerve in the Guyon's canal. I — ulnar nerve; II — deep branch of the ulnar nerve; III — superficial branch of the ulnar nerve.

Type I is characterized by injury to ulnar nerve just in the beginning of Guyon's canal — proximal from the subdivision of the nerve. The lesion considers both cutaneous and motor fibers and therefore the following symptoms develop:

- Atrophy of hypothenar muscles and middle muscles of hand supplied by ulnar nerve
- Anesthesia of the skin over hypothenar, little finger and medial surface of the annular finger on the palmar aspect.

In the second type of a lesion (type II) compression of the deep branch of ulnar nerve occurs. This is why one can see only the motor deficits associated with muscles supplied by ulnar nerve.

In the third type (type III) compression is localized next to the distal end of the canal and subjects the superficial branch of ulnar nerve. Thus sensory deficits are seen in this type only, considering the innervation of the superficial branch of ulnar nerve.

Wu *et al.* [3] proposed another subdivision, this time into five main groups of lesion (Fig. 2).

- In type I the lesion occurs in the beginning of the canal
- In type II the lesion affects the superficial branch of the ulnar nerve
- In type III the lesion affects the origin of the deep branch of the ulnar nerve, proximal from the origin of branches to hypothenar muscles
- In type IV deep branch is injured however distal from the origin of hypothenar branches
- In type V of lesion the injury covers distal fragment of the deep branch, just before it gives off last branches: to first dorsal interosseous and adductor pollicis muscles.

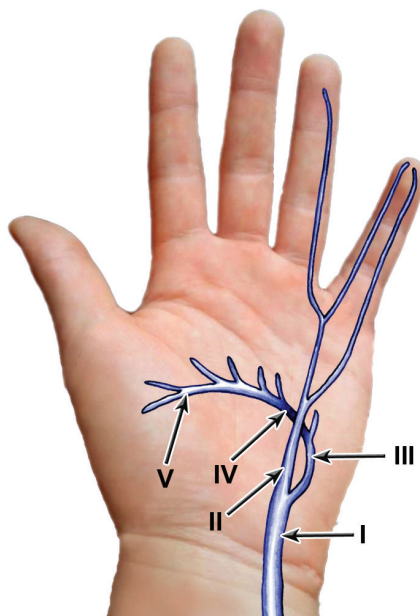


Fig. 2. Wu *et al.*'s subdivision of the lesions of ulnar nerve in the hand. I — ulnar nerve; II — superficial branch of the ulnar nerve; III — beginning of the deep branch of the ulnar nerve; IV — median portion of deep branch of ulnar nerve; V — distal portion of the deep branch of ulnar nerve.

Andreisek *et al.* [4] defines four main locations of compression of the ulnar nerve within Guyon's canal:

- Type 1 — proximal portion of canal
- Type 2 — deep branch affected — immediately after subdivision of the nerve
- Type 3 — deep branch distal from origin of branches to hypothenar
- Type 4 — superficial branch

Seddon [5] distinguished nerve lesions into three main groups:

- Neuropraxia — temporary loss of conduction abilities, associated mostly with temporary mechanical compression. After release, function returns completely.
- Axonotmesis — lesion of the axon's continuity while Schwann's coating is complete. Recovery may be complete, however it depends on many factors i.e. timing of lesion, progress of axonal regeneration, location of injury.
- Neurotmesis — complete axon and Schwann coat interruption. Complete recovery is rarely achieved.

Sunderland [6] has widened the subdivision given above into five groups.

- The first is equal to neuropraxia
- Second is equal to axonotmesis
- In the third group there is a lesion of axons and Schwann coating but the continuity of the bundles is preserved
- In the fourth group the lesion affects both endo- and epineurium
- In the fifth group there is a complete interruption of a nerve.

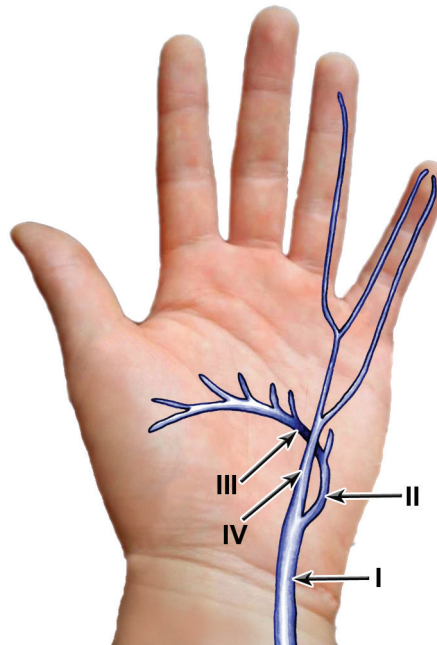


Fig. 3. Classification of ulnar nerve's lesions within Guyon's canal — after Andreisek *et al.* I — ulnar nerve; II — proximal portion of deep branch of the ulnar nerve; III — middle fragment of the deep branch of ulnar nerve; IV — superficial branch of the ulnar nerve.

Causative factors

Among the causative factors of syndrome of Guyon's canal one can distinguish:

- Tumors (ganglion, lipoma, lipo-fibroma, giant cell tumor, schwannoma, neuroma, osteoid osteoma) [7–12]
- chronic or repeatant lesions (handlebar palsy, procedures which require prolonged hyperextension of the wrist, risk of vibration — hypothenar hammer syndrome — industrial workers, sportsmen: handball, basketball, tennis, squash, golf, martial arts, break-dancers) [13, 14]
- diseases of neighboring vessels (aneurysmatic dilation of the ulnar artery, arterio-venous malformations, hemangiomas, thrombosis of the ulnar artery, giant cell arteriitis) [15–18]
- metabolic diseases (rheumatoid polyarthritis, amyloidosis, sarcoidosis, sclerodermia, diabetes) [19, 20]
- anatomical variations (additional carpal muscles or bones, the presence of piso-hamate arch, fibrosis, protruding or bifid hook of hamate bone) [21–26]
- degenerative diseases in the wrist
- idiopathic causatives [27–29].

Diagnosics

The following tst are used:

- Tinel's sign — which is based on the existence of pain by wrist percussion over the course of ulnar nerve [30, 31]
- Froment's sign — in which patient holds the piece of paper between thumb and the metacarpus and the examiner tries to withdraw it — function of the thumb, dependent on the contraction of the adductor pollicis muscle, supplied by the ulnar nerve, is replaced by the flexion of the interphalangeal joint of the thumb, dependent on the contraction of the flexor pollicis longus, supplied by the median nerve.
- palmaris brevis sign — contraction of the palmaris brevis muscle during active abduction of the little digit (differentiation between the syndrome of the ulnar nerve sulcus — lack of contraction, and the compression within the piso-hamate hiatus — contraction present) [32]
- Wartenberg's sign — positioning of the little finger in abduction [33]
- clawing of the hand
- electroneurophysiological tests (testing of the neural transduction velocity, electromyography) [34]
- classical radiology (RTG) of the wrist — i.e. projection targeted to the carpal tunnel
- ultrasonographic scanning of the wrist (USG)
- magnetic resonance (MRI) of the wrist, indicated specially in case of equivocal symptoms, suspicion of proliferation, and persisted sign although the operative treatment was carried out.

Treatment

Conservative treatment based on traumas avoidance, temporary immobilization, local administration of corticosteroids, is rarely efficacious. Lack of effects of conservative treatment or organic cause of compression in imaging is an indication for operative treatment.

Operation technique

Incision of the skin is made along the lateral margin of the flexor carpi ulnaris muscle, beginning in the distal 1/3 of the forearm. The incision is extended in the form of Z-letter at the level of proximal wrist skin crease and along the axis of the anular finger. After drawing the flexor carpi ulnaris medially, one can see the ulnar neurovascular bundle of the forearm. Further dissection, we should cut and draw medially the palmar carpal ligament, fat tissue and palmaris brevis muscle, what opens the Guyon's canal. Thus we are able to revise the course of the ulnar nerve and its branches in all three spaces, described by Shea and McClain. The compression to ulnar nerve can be disposed of. After careful hemostasis, the wound should be closes layer by layer and ensafed by sterile swab.

Complication

Postoperative complication after Guyon's canal revision are statistically rare. One can distinguish the following:

- injury to a nerve during operation
- infection of the operation site
- disturbance in the healing process
- thrombophlebitis of local veins
- deformity of the operation site
- keloid formation

In certain failures of the operative treatment it is impossible to establish the causatives. Sometimes lack of positive effect can be achieved by incomplete release of all branches of the nerve, underdiagnosed so called "double crush syndrome", associated with symutaneous compression in two locations: groove for ulnar nerve and Guyon's canal.

Conclusions

Syndrome of Guyon's canal seems to be relatively rare causative factor of compression syndromes in the wrist, however if occurs, requires very profound anatomical knowledge.

Conflict of interest

None declared.

References

1. Depukat P, Mizia E, Kłosiński M., Dzikowska M., Klimek-Piotrowska W, Mazur M., Kuniewicz M., Bonczar T: Anatomy of Guyon's canal — a systematic review. *Folia Med Cracov.* 2014; 2: 81–86.
2. Shea J.D., McClain E.J.: Ulnar nerve compression syndromes at and below the wrist. *J Bone Joint Surg [Am].* 1969; 51: 1095–1103.
3. Wu J.S., Morris J.D., Hogan G.R.: Ulnar neuropathy at the wrist: case report and review of literature. *Arch Phys Med Rehabil.* 1985; 66: 785–788.
4. Andreisek G., Crook D.W., Burg D., Marincek B., Weishaupt D.: Peripheral neuropathies of the median, radial and ulnar nerves: MR imaging features. *Radiographics.* 2006; 26 (5): 1267–1287.
5. Seddon H.: Tree types of nerve injury. *Brain* 1943; 66: 247–288.
6. Sunderland S.A.: A classification of peripheral nerve injury produced by loss of function. *Brain.* 1951; 74: 491–495.
7. Erkin G., Uysal H., Keles I., Aybay C., Ozel S.: Acute ulnar neuropathy at the wrist: a case report and review of the literature. *Reumatol Int.* 2006; 27: 191–196.
8. Okada M., Sakaguchi K., Oebisu N., Takamatsu K., Nakamura H.: A ganglion within the ulnar nerve and communication with the distal radioulnar joint via an articular branch: case report. *J Hand Surg.* 2011; 36A: 2024–2026.
9. Chen W.A., Barnwell J.C., Li Y., Smith B.P., Li Z.: An ulnar intreneural ganglion arising from the pisotriquetral joint: case report. *J Hand Surg.* 2011; 36A: 65–67.
10. Kitamura T., Oda Y., Matsuda S., Kubota H., Iwamoto Y.: Nerve sheath ganglion of the ulnar nerve. *Arch Orthop Trauma Surg.* 2000; 120: 108–109.

11. Rohilla S., Yadav R.K., Dhaulakhandi D.B.: Lipoma of Guyon's canal causing ulnar neuropathy. *J Orthopaed Traumatol.* 2009; 10: 101–103.
12. Francisco B.S., Agarwal J.P.: Giant cell tumor of tendon sheath in Guyon's canal tunnel syndrome: a case report and review of the literature. *Eplasty* 2009; 9:e8.
13. Ginanneschi F., Filippou G., Milani P., Biasella A., Rossi A.: Ulnar nerve compression neuropathy at Guyon's canal caused by crutch walking: case report with ultrasonographic nerve imaging. *Arch Phys Med Rehabil.* 2009; 90: 522–524.
14. Padua L., Insola A., LoMonaco M., Denaro F.G., Padua R., Tonali P.: A case of Guyon syndrome with neuropraxic block resolved after surgical decompression: Electroencephalography and clinical Neurophysiology 1998; 109: 191–193.
15. Jose R.M., Bragg T., Srivastava S.: Ulnar nerve compression in Guyon's canal in the presence of a tortuous ulnar artery. *J Hand Surg [Br].* 2006; 31B; 2: 200–202.
16. Kim S.S., Kim J.H., Kang H.I., Lee S.J.: Ulnar nerve compression at Guyon's canal by an arteriovenous malformation. *J Korean Neurosurg.* 2009; 45: 57–59.
17. Miyamoto W., Yamamoto S., Kii R., Uchio Y.: Vascular leiomyoma resulting in ulnar neuropathy: case report. *J Hand Surg [Am].* 2008; 33A: 1868–1870.
18. Koch H., Haas F., Pierer G.: Ulnar nerve compression in Guyon's canal due to a haemangioma of the ulnar artery. *J Hand Surg [Br].* 1998; 23B: 2: 242–244.
19. Chammas M., Meyer zu Reckendorf G., Allieu Y.: Compression of the ulnar nerve in Guyon's canal by pseudotumoral calcinosis in systemic scleroderma. *J Hand Surg [Br].* 1995; 20B: 6: 794–796.
20. Garcia S., Cofan F., Combalia A., Campistol J.M., Oppenheimer F., Ramon R.: Compression of the ulnar nerve in Guyon's canal by uremic tumoral calcinosis. *Arch Orthop Trauma Surg.* 2000; 120: 228–230.
21. Netscher D.T., Cohen V.: Ulnar nerve entrapment at the wrist: cases from a hand surgery practice. *Southern Medical Journal.* 1998; 91 (5): 451–456.
22. Hirooka T., Hashizume H., Nagoshi M., Shigeyama Y., Inoue H.: Guyon's canal syndrome. A different clinical presentation caused by an atypical fibrous band. *J Hand Surg [Br].* 1997; 22B, 1: 52–53.
23. Kelly E.J., Riaz M., O'Shaughnessy M.: An anomalous muscle in the hand. *J Hand Surg [Br].* 1998; 23B, 3: 389–390.
24. Pribyl C.R., Moneim M.S.: Anomalous Hand Muscle Found in the Guyon's Canal at Exploration for Ulnar Artery Thrombosis. *Clin Orthop Rel Res.* 1994; 306: 120–123.
25. Dimitriou C., Natsis K.: Accessory Abductor Digniti Minimi Muscle Causing Ulnar Nerve Entrapment at the Guyon's Canal: A Case Report. *Clin Anat.* 2007; 20, 8: 974–975.
26. Fong E.P., Mahaffey P.J.: Ulnar Tunnel Syndrome — An Unusual Cause. *Hand Surg.* 2000; 5 (1): 77–79.
27. Murata K., Shih J.T., Tsai T.M.: Causes of Ulnar Tunnel Syndrome: A Retrospective Study of 31 Subjects. *J Hand Surg.* 2003; 28A (4): 647–651.
28. Brutus J.P., Mattoli J.A., Palmer A.K.: Unusual Complication of an Opposition Tendon Transfer at the Wrist: Ulnar Nerve Compression Syndrome. *J Hand Surg.* 2004; 29A (4): 625–627.
29. Giuffre J.L., Shin A.Y.: Bilateral Ulnar Neuropathy Secondary to Volar Displacement of Flexor Tendons Following Open Carpal Tunnel Release: Case Report. *J Hand Surg.* 2011; 36A: 2027–2029.
30. Davis E.N., Chung K.C.: The Tinel sign: a historical perspective. *Plast Reconstr Surg.* 2004; 114 (2): 494–499.
31. Alfonso M., Dzwierzynski W.: Hoffman-Tinel sign. The realities. *Phys Med Rehabil Clin N Am.* 1998; 9 (4): 721–736.
32. Pleet A.B., Massey E.W.: Palmaris brevis sign in neuropathy of the deep palmar branch of the ulnar nerve. *Ann Neurol.* 1978; 3: 468–469.
33. Voche P., Merle M.: Wartenberg's Sign. A new method of surgical correction. *J Hand Surg.* 1995; 20B, 1: 49–52.
34. Tapadia M., Mozaffar T., Gupta R.: Compressive Neuropathies of the Upper Extremity: Update on Patophysiology, Classification, and Electrodiagnostic Findings. *J Hand Surg* 2010; 35A: 668–677.