

PAWEŁ DEPUKAT¹, EWA MIZIA¹, HELENA ZWINCZEWSKA¹, TOMASZ BONCZAR¹,
MAŁGORZATA MAZUR¹, MIROSLAWA DZIKOWSKA², PIOTR PEŁKA³, ALEKSANDRA MATUSZYK¹

TOPOGRAPHY OF ULNAR NERVE AND ITS VARIATIONS WITH SPECIAL RESPECT TO CARPAL REGION

Abstract: Ulnar nerve supplies small muscles of the hand and apart from the median nerve is the main coordinator of precise movements performed both in the medical and dental practice. Based on their anatomical and clinical experience, authors revised a knowledge on this nerve with special respect to its topography, variation in the wrist.

Key words: ulnar nerve, wrist, Guyon's canal, anatomy.

INTRODUCTION

Ulnar nerve begins in the axillary fossa as a main branch of the medial cord of infraclavicular part of brachial plexus (C8-T1). It runs medial to axillary artery and lateral to the vein and exits to the arm into the medial bicipital sulcus. It gradually leaves a companionship of brachial artery running toward the back, pierces the medial intermuscular septum in its middle part and next goes obliquely from above and front to the bottom and back. In 70–80% of cases ulnar nerve courses in its location through a canal, composed of thin fibrous and muscular band, which extends between the medial head of triceps brachii and the medial intermuscular septum (arcade of Struthers) [1]. The nerve leaves the canal and gives off the branches to elbow joint and next runs rather superficial beneath the skin, fascia and retinaculum (epicondylo-olecranon ligament, Osborne band) [1], in the groove for ulnar nerve, over the medial humeral epicondyle. Next it traverses the forearm, going between the ulnar and humeral heads of flexor carpi ulnaris muscle, supplying them.

It courses next between flexor carpi ulnaris and flexor digitorum profundus, medial to the ulnar vessels, giving off branches to part of the flexor digitorum profundus which controls IV and V fingers. In the mid-forearm ulnar nerve gives rise to vascular branch to the ulnar artery (nerve of Henle). In the distal forearm it gives rise to ramus dorsalis manus, which winds around the body of ulna and

runs beneath the tendon of flexor carpi ulnaris. The ramus dorsalis manus gets to the dorsal surface of distal forearm and divides into medial, intermediate, and lateral branches, which subsequently divide distally into dorsal digital nerves. Continuation of the main trunk of the ulnar nerve, known as ramus palmaris manus, runs lateral and posterior to the tendon of flexor carpi ulnaris and medial to the ulnar vessels. It enters between the carpal volar ligament and flexor retinaculum, where it can give rise to a palmar cutaneous branch. Ramus palmaris manus is usually divided within its course through the Guyon's canal [2] — into superficial and deep branches — Fig 1.

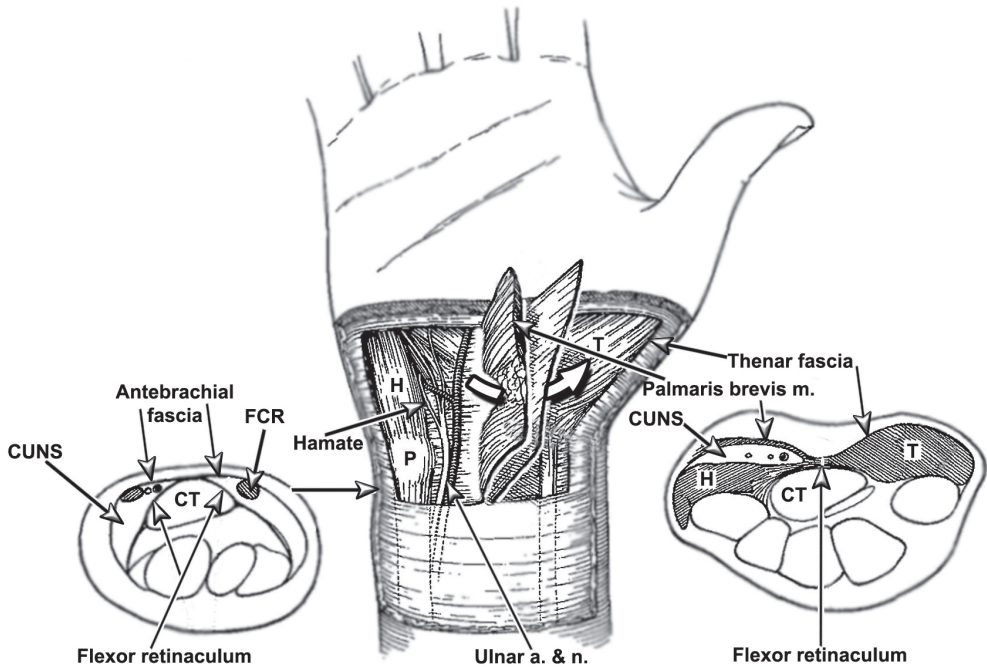


Fig. 1. Canal of Guyon.

Superficial branch runs beneath the roof of the canal giving off a branch to palmaris brevis muscle and commonly a connecting branch to a median nerve. Next it runs medial, lateral or anterior to hook of hamate [3]. And divides into palmar common digital nerve of anular finger. The deep branch runs medial and posterior entering the piso-hamate hiatus, and giving off branches to hypothenar. Next it courses between the superficial and the deep layers of opponens digiti minimi muscle and winds over the hook of hamate, running next laterally. It runs along the palmar aspect of metacarpal and palmar interossei giving off branches to palmar and dorsal interossei and lumbricals III and IV, also vascular and articular rami. In the end it reaches thenar muscles: adductor pollicis and deep head of flexor pollicis brevis.

VARIATION

Numerous authors describe different variations of origin of ulnar nerve from the brachial plexus: it can originate from the median nerve or it can be a direct continuation of T1. It may also arise from two roots: the main arising from the lateral or medial root of the median nerve, from anterior division of middle trunk of the brachial plexus or from radial nerve. During its course in the arm ulnar nerve can anastomose with the median nerve, and run posterior to the brachial artery. In the forearm it may join the median nerve with a branch which runs behind the flexor digitorum superficialis muscle. Ramus dorsalis manus can anastomose in the forearm with the medial cutaneous nerve of forearm in its distal portion and on the dorsal aspect of the hand with the lateral cutaneous nerve of forearm or/and with the superficial radial nerve. There are numerous variations described in the palm of the hand:

- Deep branch can unite with medial dorsal digital nerve of the V-th finger
- Perforating rami of deep branch of ulnar nerve with posterior interosseous nerve
- Terminal portion of deep branch with motor branch to flexor pollicis brevis
- There is a permanent connection between superficial branch of ulnar nerve with palmar common digital nerve of III and IV digits (Berettini branch) [1, 4–8].

It was Kaplan [8] who described in 1963 for the first time connection between the medial proper palmar digital nerve of V-th finger with ramus dorsalis manus. Medial proper palmar digital nerve of V-th finger originated from ramus dorsalis manus and ran medial to pisiform, did not entering the Guyon's canal. It anastomosed with superficial branch of ulnar nerve and next separately reached the ulnar margin of the V-th finger (Fig. 2).

Bozkurt *et al.* [9] described medial proper palmar digital nerve of V-th finger and a branch of ramus dorsalis manus. In the metacarpus it anastomosed with branches from superficial branch of ulnar nerve to supply palmaris brevis muscle. In the same case superficial branch of ulnar nerve divided into lateral proper palmar digital nerve of little finger and medial proper palmar digital nerve of annular finger. A small branch ran from the radial side of superficial branch of ulnar beneath origin of flexor digiti minimi brevis and tendon of opponens digiti minimi and united again with the superficial branch of ulnar nerve — Fig. 3.

Windisch (2005) [10] described also medial proper palmar digital nerve of V-th finger as a branch of the ramus dorsalis manus. It traversed the palmar aspect of the hand at the level of metacarpophalangeal joint, giving off the branches to dorsal aspect of the ulnar margin of little finger. Similar variation was described by Mc Carthy *et al.* [11] and Konig *et al.* [12]. Following Hoogbergen and Kauer's report (1992) [13] analogous branch united with deep branch of ulnar nerve.

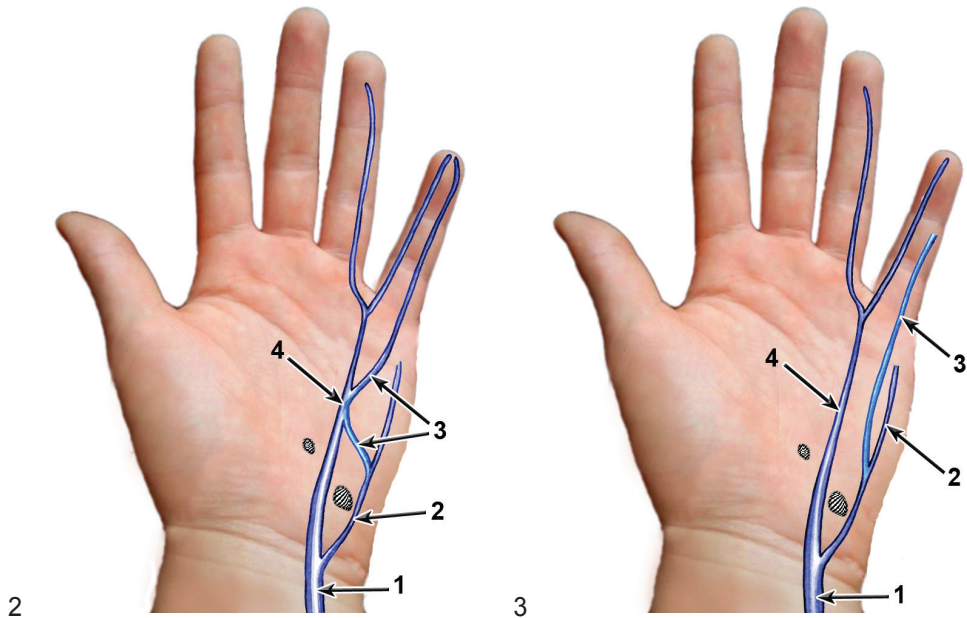


Fig. 2. Course of the medial proper palmar digital nerve of the V-th finger (after Kaplan *et al.*).

1 — ulnar nerve; 2 — ramus dorsalis manus; 3 — medial proper palmar digital nerve of the V-th finger;
4 — superficial branch of the ulnar nerve

Fig. 3. Course of the medial proper palmar digital nerve of the V-th finger (after Bozkurt *et al.*).

Hankins *et al.* (2005) [14] described similar case and divided this variation into six different types depending on the course and termination:

- In type I a branch which starts from ramus dorsalis manus, reaches the ulnar nerve within Guyon's canal, proximal from its subdivision into superficial and deep branches — Fig. 4
 - 5 — deep branch of ulnar nerve
 - 6 — described first type of branching pattern
- In type II an analogous branch reaches the superficial branch — Fig. 5
 - 6 — described type of branching pattern
- In type III described branch reaches the deep branch — Fig. 6
 - 6 — described third type of branching pattern
- In type IV the branch ends in the medial proper palmar digital nerve of the V-th finger at the level of the mid-height of the hypothenar (Fig. 7)
 - 6 — described fourth type of the branching pattern
- In the fifth type the branch goes to the medial proper palmar digital nerve of the V-th finger at the level of proximal interphalangeal joint
 - 6 — described fifth type of branching pattern

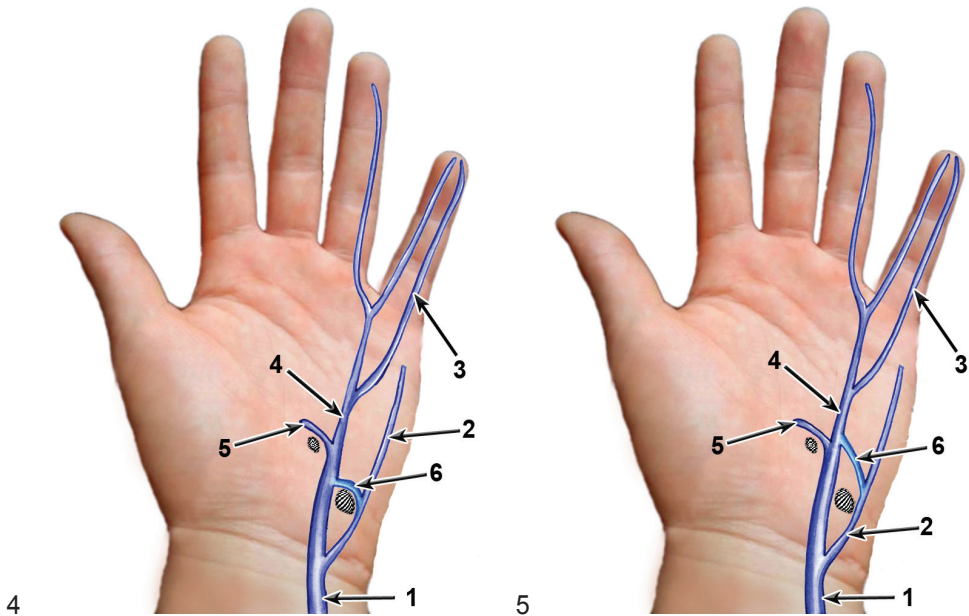


Fig. 4. Course of the medial proper palmar digital nerve of the V-th finger (after Hankins *et al.*).

Fig. 5. Course of the medial proper palmar digital nerve of the V-th finger (after Hankins *et al.*).

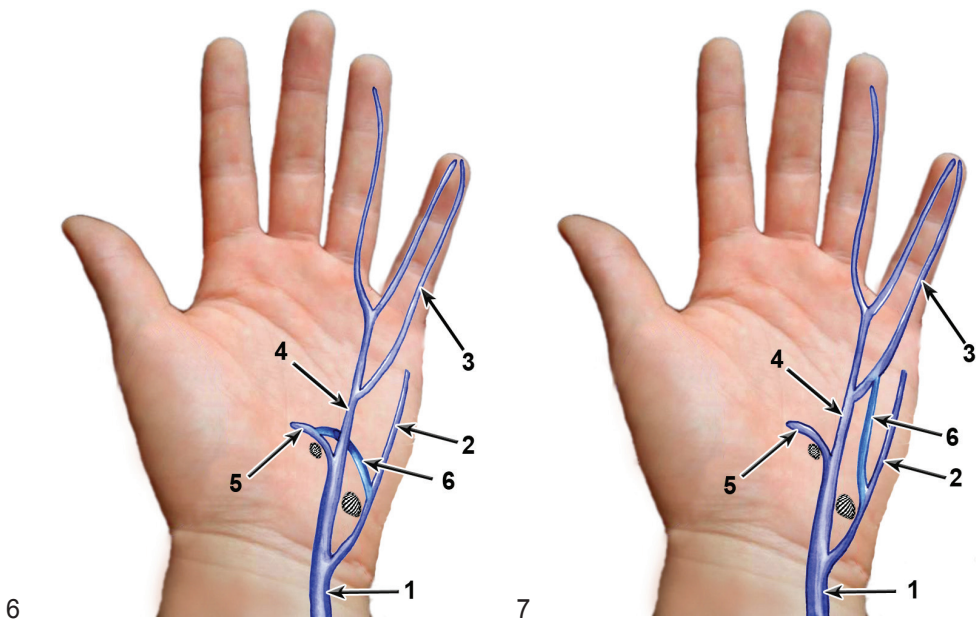


Fig. 6. Course of the medial proper palmar digital nerve of the V-th finger (after Hankins *et al.*).

Fig. 7. Course of the medial proper palmar digital nerve of the V-th finger (after Hankins *et al.*).

- In the sixth type the branch goes to radial side of the palmar aspect of the little finger. In this case the termination of this branch has been precisely established (Fig. 9)

6 — described sixth type of branching pattern

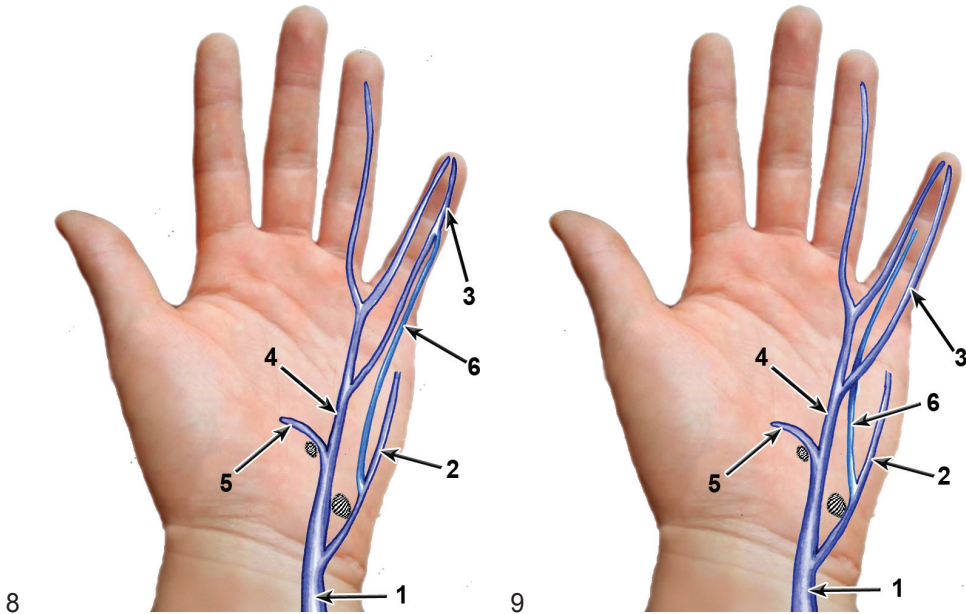


Fig. 8. Course of the medial proper palmar digital nerve of the V-th finger (after Hankins *et al.*).

Fig. 9. Course of the medial proper palmar digital nerve of the V-th finger (after Hankins *et al.*).

Bozkurt *et al.* [15] in 2004 presented a case of an additional branch of ulnar nerve, which originated from the main trunk about 13 cm proximally from the pisiform bone, which ran together with ulnar artery through the Guyon's canal, and reached the radial aspect of the anular finger. During its course it united with palmar common digital nerve of little and anular fingers in the fourth interosseous space. It received also two additional branches from palmar common digital nerve of the anular and middle fingers within the third interosseous space: first branch at the level of distal border of flexor retinaculum and the second at the level of the proximal metacarpophalangeal joint of the anular finger — Fig. 10.

Martin *et al.* [16] in 1995 observed variability of ulnar nerve regarded to cutaneous supply of the hand and distinguished three main groups of branching pattern:

- first was a classical cutaneous branch of the ulnar nerve. It originated from the main trunk in the distal forearm, running superficial to the transverse carpal ligament and the palmaris brevis muscle — Fig. 11.

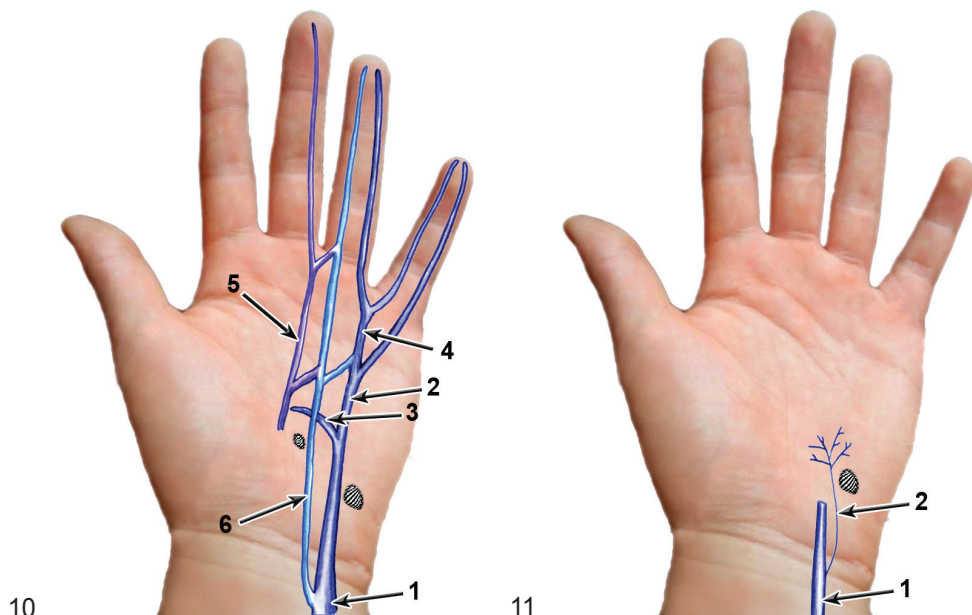


Fig. 10. Additional branch of ulnar nerve (after Bozkurt *et al.*).

1 — ulnar nerve; 2 — superficial branch of ulnar nerve; 3 — deep branch of ulnar nerve; 4 — palmar common digital nerve of IV and V fingers; 5 — palmar common digital nerve of III and IV fingers 6 — described additional branch

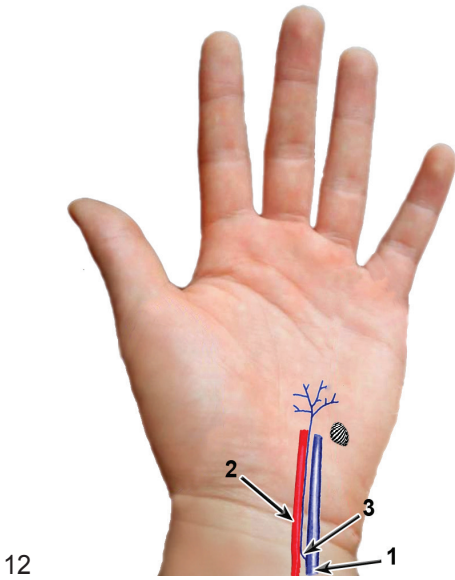
Fig. 11. "Classic" palmar cutaneous branch (after Martin *et al.*).

1 — ulnar nerve; 2 — palmar cutaneous branch

- second group was established by branches of nerve of Henle which enables autonomic innervation of the ulnar artery, but innervates the skin of the forearm and hand, too (Fig. 12).
- third group was made by cutaneous nerves which originated from the ulnar nerve distal from the proximal carpal crease, within Guyon's canal, most frequently running at right angle with respect to axis of the ulnar nerve (Fig. 13).

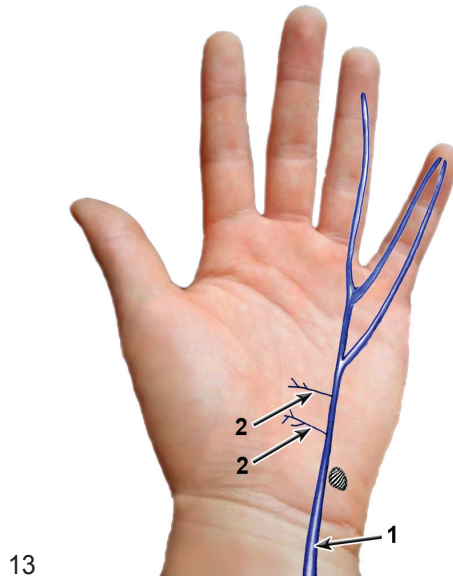
Lindsey *et al.* [17] in 1995 presented two division patterns of ulnar nerve within Guyon's canal, and classified them as group A or B.

- In group A (25 out of 31 wrists studied) ulnar nerve was "classically" subdivided into superficial and deep branches. In 20 of cases the subdivision occurred within Guyon's canal, about 8.6 mm distal from the proximal end of pisiform. In 5 remaining cases bifurcation was located proximal to the wrist, about 12,6 mm proximal from the proximal end of the pisiform (Fig. 14).
- In group B (6 out of 31 wrists) ulnar nerve was divided into three branches: deep, proper palmar digital nerve of the little finger and common digital nerve of the little and anular digits. In all cases the subdivision occurred within Guyon's canal, about 10 mm distal from the proximal end of pisiform (Fig. 15).



12

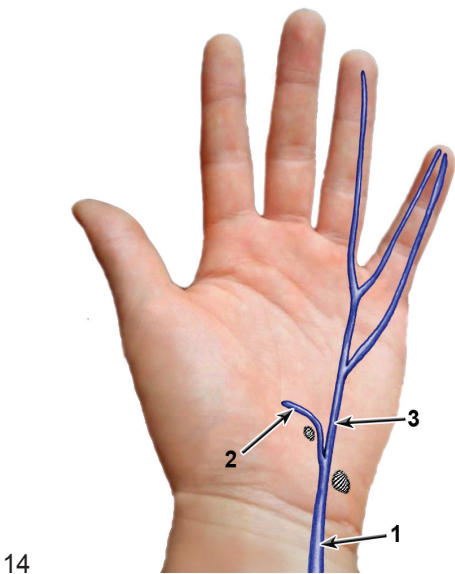
Fig. 12. Branching pattern from nerve of Henle (after Martin *et al.*).
1 — ulnar nerve; 2 — ulnar artery; 3 — nerve of Henle



13

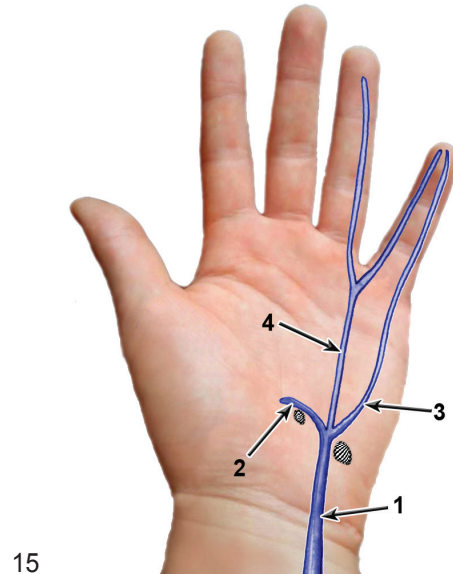
Fig. 13. Branching pattern of cutaneous branches originating within the Guyon's canal (after Martin *et al.*).

1 — ulnar nerve; 2 — cutaneous branches



14

Fig. 14. "Classic" subdivision of the ulnar nerve within Guyon's canal (after Lindsey *et al.*).
1 — ulnar nerve; 2 — deep branch of ulnar nerve; 3 — superficial branch of ulnar nerve



15

Fig. 15. Subdivision of ulnar nerve within Guyon's canal into three branches (after Lindsey *et al.*).
1 — ulnar nerve; 2 — deep branch of ulnar nerve; 3 — medial proper palmar digital nerve of the little finger;
4 — palmar common digital nerve of the little and anular digits

In the study given above authors noticed also different patterns of hypothenar muscles innervation.

- In type 1 — single branch originated from the deep branch of ulnar nerve (10 out of 31 wrists studied), proximal to or at the border with abductor digiti minimi muscle, reaching the opponens and flexor digiti minimi brevis (Fig. 16).
- In type 2 (14 out of 31 wrists) two branches ran to hypothenar, and first of them used to bifurcate into next two (Fig. 17)

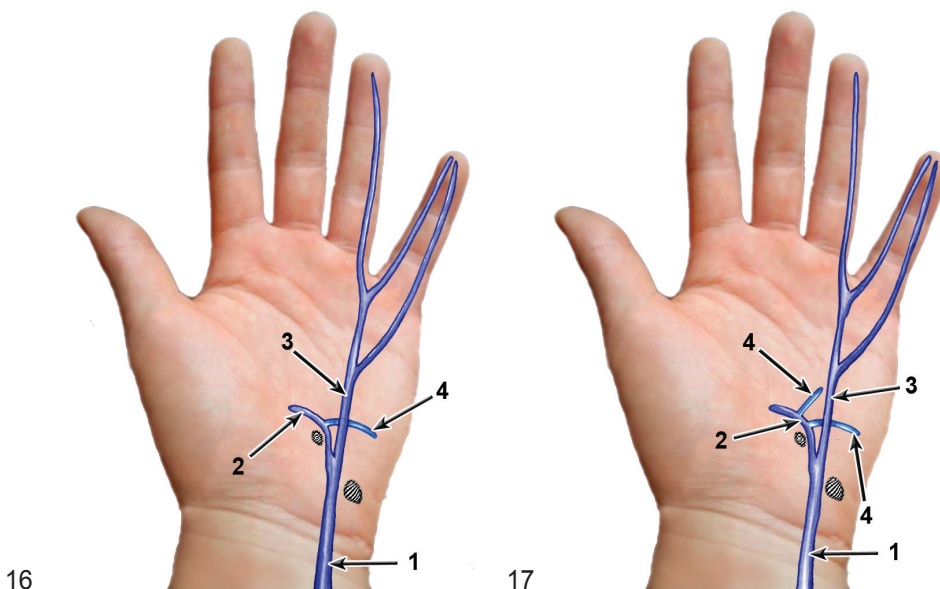


Fig. 16. First type of hypothenar muscles innervation (after Lindsey *et al.*).

1 — ulnar nerve; 2 — deep branch of ulnar nerve; 3 — superficial branch of ulnar nerve; 4 — branch to hypothenar muscles — described above

Fig. 17. Branching pattern of second type of hypothenar innervation (after Lindsey *et al.*).

1 — ulnar nerve; 2 — deep branch of ulnar nerve; 3 — superficial branch of ulnar nerve; 4 — branch to hypothenar

- In type 3 (7 out of 31 wrists) three or more branches ran to hypothenar. In general about 73% of branches originated within Guyon's canal, 25% distal from canal and only one branch proximally (Fig. 18).

Murata *et al.* (18) in 2004 distinguished 5 main patterns of subdivision of ulnar nerve within the Guyon's canal:

- In type 1 (27 out of 35 wrists studied) ulnar nerve was subdivided into two branches: superficial and deep, distal to the distal end of pisiform. Superficial branch divided into proper palmar digital nerve of little finger and IV palmar common digital nerve. In one case they found a connecting branch between cutaneous branches (Fig. 19).

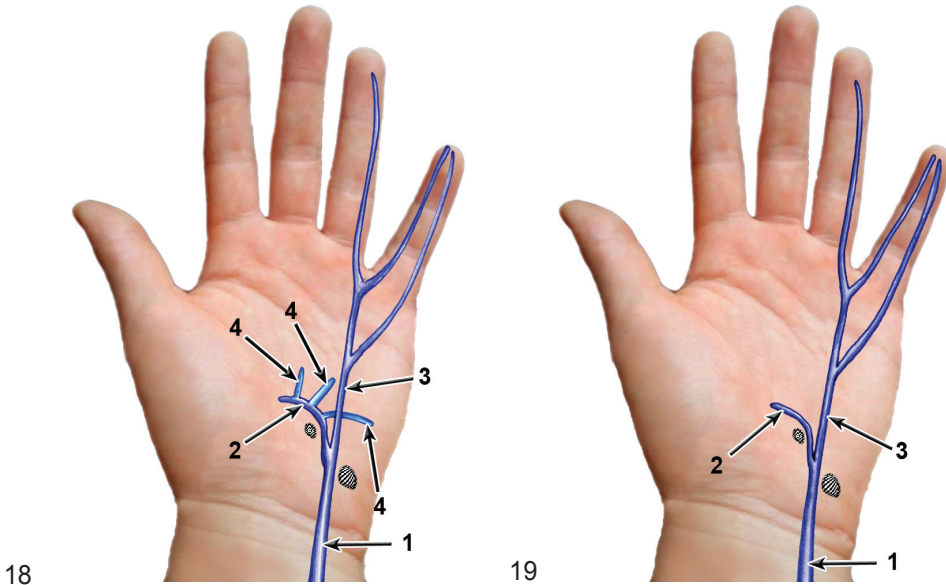


Fig. 18. Third type of hypothenar branching pattern (after Lindsey *et al.*).

1 — ulnar nerve; 2 — deep branch of ulnar nerve; 3 — superficial branch of ulnar nerve; 4 — branches to hypothenar

Fig. 19. Branching pattern of type 1 of subdivision of ulnar nerve within Guyon's canal (after Murata *et al.*).

1 — ulnar nerve; 2 — deep branch of ulnar nerve; 3 — superficial branch of ulnar nerve

- In type 2 (3 out of 35 wrists studied) ulnar nerve was subdivided distal from the distal end of pisiform into three branches — deep branch, proper palmar digital nerve of V-th digit, IV palmar common digital nerve (Fig. 20).
- In type 3 (3 out of 35 wrists studied) ulnar nerve divided distal from a distal end of pisiform into two trunks: ulnar and radial. Radial trunk was continuous with palmar common digital nerve of IV-th digit; ulnar trunk divided into deep branch of ulnar and proper palmar digital nerve of V-th digit, which pierced abductor digiti minimi. In one case a connecting branch between cutaneous branches was found (Fig. 21).
- In type 4 (1 out of 35 wrists studied) one could see subdivision into three branches, similar to type 2, but proximal from subdivision, an additional branch was arising. It pierced abductor digiti minimi and reached proper palmar digital nerve of V-th digit. In this type a branch which united two cutaneous branches was also observed (Fig. 22).
- In type 5 (1 out of 35 wrists studied) main trunk was subdivided into three branches, similar to type 2. However a certain junction which ran through a belly of abductor digiti minimi was observed. It ran between ramus dorsalis manus and medial proper palmar digital nerve of the little finger (Fig. 23).

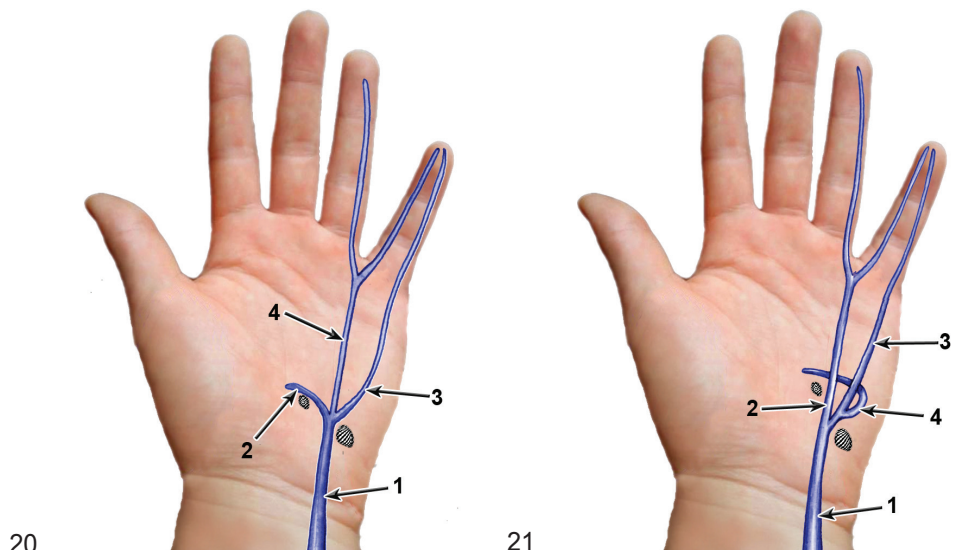


Fig. 20. Type 2 of branching pattern of subdivision of ulnar nerve in Guyon's canal (after Murata *et al.*).
1 — ulnar nerve; 2 — deep branch of ulnar nerve; 3 — superficial branch of ulnar nerve; 4 — palmar common digital nerve of IV and V-th digits

Fig. 21. Type 3 of branching pattern of subdivision of ulnar nerve in Guyon's canal.
1 — ulnar nerve; 2 — radial trunk; 3 — ulnar trunk; 4 — deep branch of ulnar nerve

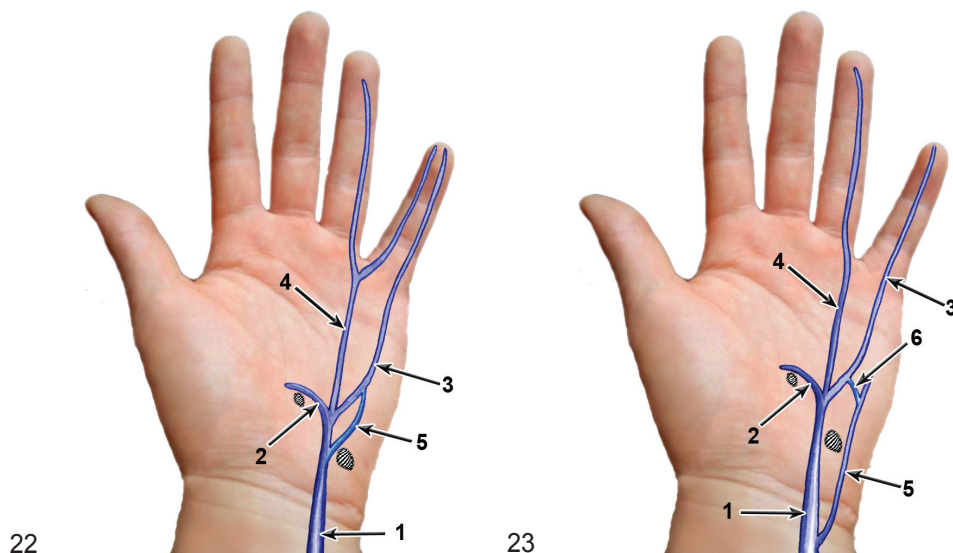


Fig. 22. Type 4 of branching pattern of ulnar nerve in Guyon's canal (after Murata *et al.*).
1 — ulnar nerve; 2 — deep branch of ulnar nerve; 3 — proper palmar digital nerve of the V-th digit;
4 — palmar common digital nerve of IV and V-th digits; 5 — additional branch — described above

Fig. 23. Type 5 of branching pattern of ulnar nerve in Guyon's canal (after Murata *et al.*).
1 — ulnar nerve; 2 — deep branch of ulnar nerve; 3 — medial proper palmar digital nerve of V-th digit; 4 — common palmar digital nerve of the IV and V-th digits; 5 — ramus dorsalis manus; 6 — additional connecting branch — described above
These authors distinguished also four patterns of hypothenar innervation.

- In type 1 (16 out of 35 wrists) motor branch to hypothenar was arising from deep branch of ulnar nerve distal to the piso-hamate hiatus (Fig. 24).
- In type 2 (1 out of 35 wrists studied) main motor branch to hypothenar arose from deep branch of ulnar nerve, proximal from the hiatus, within Guyon's canal. Additional branch begun distal from hiatus (Fig. 25).

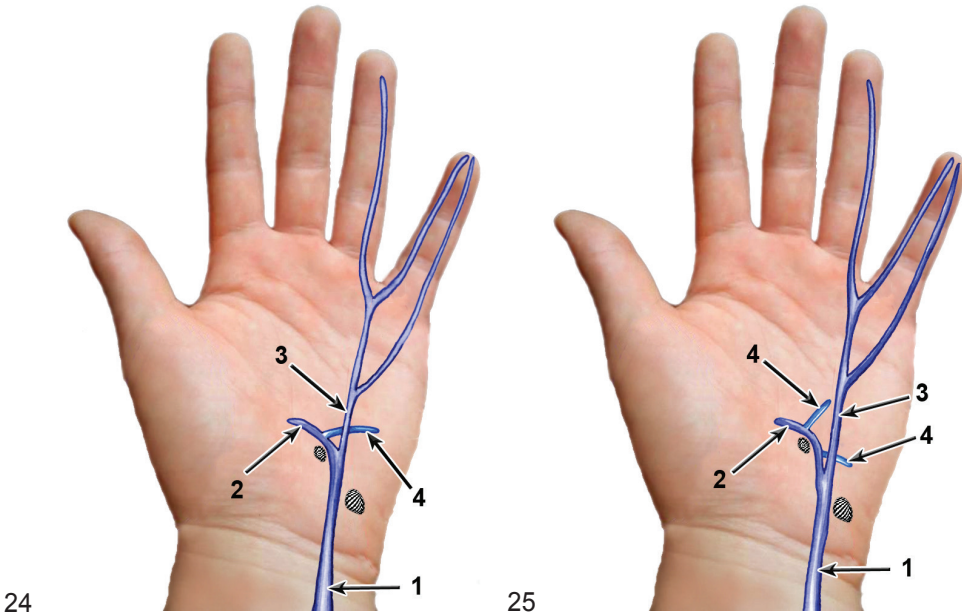


Fig. 24. Type 1 of branching pattern of ulnar nerve to hypothenar muscles (after Murata *et al.*).
1 — ulnar nerve; 2 — deep branch of ulnar nerve; 3 — superficial branch of ulnar nerve;
4 — branch to hypothenar muscles

Fig. 25. Type 2 of branching pattern of hypothenar innervation (after Murata *et al.*).
1 — ulnar nerve; 2 — deep branch of ulnar nerve; 3 — superficial branch of ulnar nerve; 4 — branches to hypothenar

- In type 3 (8 out of 35 wrists studied) motor branch to hypothenar originated within Guyon's canal at the level of its subdivision into deep and superficial branches (Fig. 26).
- In type 4 (10 out of 35 wrists studied) motor branch to hypothenar originated from a trunk of ulnar nerve in Guyon's canal, proximal to subdivision of ulnar nerve. In 4 cases an additional branch existed. It originated distal from hiatus (Fig. 27).

The distribution of branches to hypothenar muscles was as follows:

1 branch in 8 hands; 2 — in 17 hands; 3 in 9 hands; 4 in 1 hand. The authors observed also a phenomenon of innervation of few bellies by a single branch and one belly by few branches. In 22 of cases a branch which connected median and ulnar nerves was found.

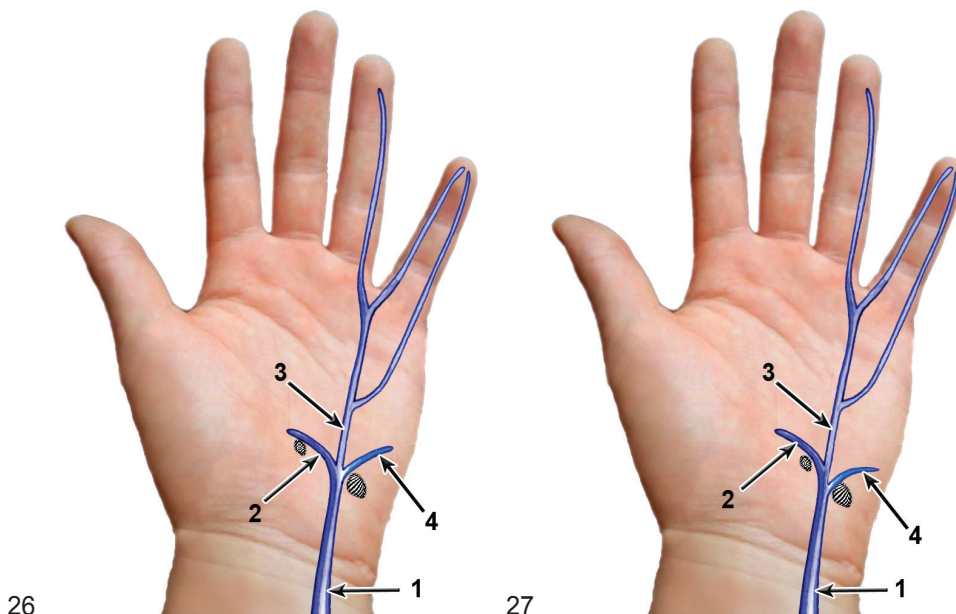


Fig. 26. Type 3 of branching pattern of hypothenar innervation (after Murata *et al.*).

1 — ulnar nerve; 2 — deep branch of ulnar nerve; 3 — superficial branch of ulnar nerve; 4 — branch to hypothenar

Fig. 27. Type 4 of branching pattern of innervation of hypothenar muscles (after Murata *et al.*).

1 — ulnar nerve; 2 — deep branch of ulnar nerve; 3 — superficial branch of ulnar nerve; 4 — branch to hypothenar

CONCLUSION

Ulnar nerve in its termination point at the wrist show various combinations of its subdivision with special respect to the region of Guyon's canal and branching pattern to hypothenar muscles.

CONFLICT OF INTERESTS

None declared.

REFERENCES

1. Andreisek G., Crook D.W., Burg D., Marincek B., Weishaupt D.: Peripheral neuropathies of the median, radial and ulnar nerves: MR imaging features. *Radiographics*. 2006; 26: 1267–1287. — 2. Depukat P., Mizia E., Kłosiński M., Dzikowska M., Klimek-Piotrowska W., Mazur M., Kuniewicz M., Bonczar T.: Anatomy of Guyon's canal — a systematic review. *Folia Med Cracov*. 2014; 54 (2): 81–86. — 3. Blum A.G., Zabel J.P., Kohlmann R., Batch T., Barbara K., Zhu X., Dautel G., Dap F.: Pathologic

conditions of the hypothenar eminence: evaluation with multidetector CT and MRI imaging. *Radiographics*. 2006; 26 (4): 1021–1044. — **4.** *Cobb T.K., Carmichael S.W., Cooney W.P.*: Guyon's canal revisited: an anatomic study of the carpal ulnar neurovascular space. *J Hand Surg*. 1996; 9 : 861–869. — **5.** *Lancerotto L., Tiengo C., Stecco C., Macchi V., Bassetto F., Caro R.D.*: Wrist fascial anatomy: is everything known. *J Hand Surgery*. 2009; 34E: 125–126. — **6.** *Zeiss J., Jakab E., Khinji T., Imbriglia J.*: The ulnar tunnel at the wrist (Guyon canal): normal MR anatomy and variants. *AJR Am J Roentgenol*. 1992; 158 (5): 1081–1085. — **7.** *Bozkurt M.C., Tagil S.M., Ozcakar L., Ersoy M., Tekdemir I.*: Anatomical variations as potential risk factors for ulnar tunnel syndrome. *Clin Anat*. 2005; 18: 274–280. — **8.** *Kaplan E.B.*: Variation of the ulnar nerve at the wrist. *Bull Hosp Joint Dis*. 1963; 24: 85–88. — **9.** *Bozkurt E., Cezayirli E., Tagil S.M.*: An unusual termination of the ulnar nerve in the palm. *Ann Anat*. 2002; 184: 271–273. — **10.** *Windisch G.*: Unusual vascularization and nerve supply of the fifth finger. *Ann Anat*. 2006; 188: 171–175.

11. *McCarthy R., Nalebuff E.*: Anomalous volar branch of the dorsal cutaneous ulnar nerve: a case report. *J Hand Surg*. 1980; 5: 19–20. — **12.** *Konig P.S., Hage J.J., Bloem J.J., Prose L.P.*: Variations of the ulnar nerve and ulnar artery in Guyon's canal: a cadaver study. *J Hand Surg [Am]*. 1994; 19 (4): 617–622. — **13.** *Hoogbergen M.M., Kauer J.M.G.*: An unusual ulnar nerve- median nerve communicating branch. *J Anat*. 1992; 181: 513–516. — **14.** *Hankins C.L., Flemming S.*: A variant of Kaplan's accessory branch of the dorsal cutaneous branch of the ulnar nerve: a case report and review of the literature. *J Hand Surg*. 2005; 30A: 1231–1235. — **15.** *Bozkurt M.C., Tagil S.M., Ersoy M., Tekdemir I.*: Muscle variations and abnormal branching and course of the ulnar nerve in the forearm and hand. *Clin Anat*. 2004; 17: 64–66. — **16.** *Martin C.H., Seiler J.G., Lesesne J.S.*: The cutaneous innervation of the palm: an anatomic study of the ulnar and median nerves. *J Hand Surg [Am]*. 1996; 21 (4): 634–638. — **17.** *Lindsey J.T., Watumull D.*: Anatomic study of the ulnar nerve and related vascular anatomy at Guyon's canal: a practical classification system. *J Hand Surg [Am]*. 1996; 21 (4): 626–633. — **18.** *Murata K., Tamai M., Gupta A.*: Anatomic study of variations of hypothenar muscles and arborisation patterns of the ulnar nerve in the hand. *J Hand Surg [Am]*. 2004; 29A: 500–509.

¹ Department of Anatomy
Jagiellonian University Medical College
ul. Kopernika 12, 31-034 Kraków, Poland
Head: prof. dr hab. Jerzy Walocha

² Department of Clinical Nursing
Jagiellonian University Medical College
ul. Kopernika 25, 31-501 Kraków Poland
Head: dr hab. Maria Kózka

³ Department of Orthodontics
Jagiellonian University Medical College
ul. Montelupich 4, 31-155 Kraków, Poland
Head: prof. dr hab. Bartłomiej Loster

Corresponding author:
Paweł Depukat, MD PhD
Department of Anatomy
Jagiellonian University Medical College
ul. Kopernika 12, 31-034 Kraków, Poland
depukatp@poczta.onet.pl